THE NEW YORK AFRICAN BURIAL GROUND:
Unearthing the African Presence in Colonial New York

Volume 1

The Skeletal Biology of the New York African Burial Ground

Part 2: Burial Descriptions and Appendices

Michael L. Blakey and Lesley M. Rankin-Hill
Editors

HOWARD UNIVERSITY PRESS
WASHINGTON, D.C.
2009

Published in association with the United States General Services Administration

Skeletal Biology of the African Burial Ground, Part 2 (2009), was published formerly as the *Skeletal Biology Final Report, Volume II* (2004), and was posted on the World Wide Web at http://www.africanburialground.gov/ABG_FinalReports.htm. *Skeletal Biology of the African Burial Ground, Part 2,* will be posted on the Web site of the National Park Service at http:www.nps.gov.

Application has been filed for Library of Congress registration.

Any opinions, findings, and conclusions or recommendations expressed in this material are those of the authors and do not necessarily reflect the views of the U.S. General Services Administration or Howard University.

Published by Howard University Press
2225 Georgia Avenue NW, Suite 720
Washington, D.C. 20059
18 17 16 15 14 13 12 11 10 09 1 2 3 4 5
ISBN 0-88258-253-4
978-0-88258-253-5

Howard University's New York African Burial Ground Project was funded by the U.S. General Services Administration under Contract No. GS-02P-93-CUC-0071

Technical editing and graphics support by Statistical Research, Inc.
Layout and design by Simpson & Convent.

Typeset and printed in the United States of America.
Printed on acid-free paper.

Cover Images:

Detail of the Maerschalk Plan (Francis Maerschalk, 1754)

Artifacts from the New York African Burial Ground (Photographs by Jon Abbott):

Enameled cuff link face, Burial 371, Catalog No. 1875-B.001.
Bead Type 12, Burial 340, Catalog No. 01651-B.79.
Oval turquoise enamel face, Burial 211, Catalog No. 1186 -B.001.
Pins, Burial 12, Catalog Nos. 253-B.001, .002.
Ring, copper alloy with glass insets, Burial 310, Catalog No. 1486-B.001.
Bead Type 9, Burial 340, Catalog No. 01651-B.78.
Bead Type 15, Burial 340, Catalog No. 01651-B.75.
Button, bone, turned. Burial 171, Catalog No. 931-B.002.
Cast silver pendant, Burial 254, Catalog No. 1243-B.001.

Burial 335 (Photography by Dennis Seckler)

Cover design by Star Bullock + Associates, Mark A. Bartley

Contributors

PROJECT DIRECTOR AND SCIENTIFIC DIRECTOR

Michael L. Blakey, Ph.D.

LABORATORY DIRECTOR AND OSTEOLOGIST

Mark E. Mack, M.A.

OFFICE MANAGER AND ADMINISTRATIVE ASSISTANT

Reba Brewington, B.A.

OSTEOLOGIST

M. Cassandra Hill, M.A., Ph.D.*

OSTEOLOGICAL TECHNICIANS

Autumn Barrett, M.A., A.B.D.*
Allison Davis
Reynard Davis (deceased)
Ena Fox
Shannon Mahoney, M.A., A.B.D.*
Susan Good-Null, M.A., Ph.D.*
Monde Imoh, Ph.D.
Christopher Null, M.A., A.B.D.*
Kenya Shujaa, M.A.*
Rachel Watkins, M.A., Ph.D.*

OSTEOLOGICAL TECHNICIAN ASSISTANTS

Valarian Abrams
Paula Allen
Marc Alston
Darious Annis
Augustus Billy
Alan Blanc
Antonia Christian
Jeffrey Coleman
Lauren Collins
Cyndi Douglas Jacinta Elder-Arrington
Nardos Fessaha, Ph.D.*
April Flint
Gabriel Franke, M.A.
Paul Gattis
Oumuyiwa Gbadegesin
Richlyn Goddard, Ph.D.
Karyn Goodwin
Yasin Gregg
Janna Gruber
Fayola Herod
Michael Hunter
Keisha Hurst
Joseph Jones, M.A.*, A.B.D.*
Antoinette Kearney
Irina Koretsky, M.S.
Dannette Lambert
Teresa Leslie, M.A.,* Ph.D.*
Arion Mayes, M.A., Ph.D.*
Moses Nwulia
Auriel Perkins
Keisha Rankine
Clifford Russell
Joann Sampson
Jobita Smith
Azhar Talibi, M.A., M.D.*
Brent Terry, M.A.
Emile Webster
Shani Wright

RESEARCH ASSISTANTS

Pamela Brown
Songhai Carter
Christa Dickey
Lesley Payne
Arana Hankin
Nicole Harvey
Jeffrey Lim
Chad Taylor
Walidah West

SENIOR MEDICAL PHOTOGRAPHER

Otto Edwards

DATA SYSTEMS MANAGER

Douglas Fuller, M.A.
Javier Urcid, Ph.D.
Christopher Null

SECRETARIES

Denise Joseph
Marna Lewis
Andrea Reid
Raquel Scott
Percival Taylor
Sharon Wiltshire

BOTANISTS

Lafayette Frederick, Ph.D.
Monde Emoh, Ph.D.

CONSULTANTS FOR THIS REPORT

Richard Kittles, Ph.D.
Matthew George, Ph.D.
Thomas Stafford, Ph.D.
Shomarka O.Y. Keita, M.S., M.A., M.D.

AFRICAN BURIAL GROUND PROJECT DIRECTORS

Michael L Blakey, Ph.D., Scientific Director, College of William and Mary, and Howard University
Edna Medford, Ph.D., Associate Director for History, Howard University
Sherrill D. Wilson, Ph.D., Director, Office of Public Education and Interpretation
Alan H. Goodman, Ph.D., Associate Director for Chemical Studies, Hampshire College
Jean Howson, Ph.D., Archaeology Laboratory Director, Howard University
Fatimah L. C. Jackson, Ph.D., Associate Director for Genetics, University of Maryland
Mark E. Mack, M.A., Cobb Laboratory Director, Howard University
Warren Perry, Ph.D., Associate Director for Archaeology, Central Connecticut State University
Lesley M. Rankin-Hill, Ph.D., Associate Director for Skeletal Biology, University of Oklahoma
Warren Barbour, Ph.D., Associate Director (1992–1994)

AFRICAN BURIAL GROUND PROJECT ADMINISTRATION/MANAGEMENT

O. Jackson Cole, Ph.D., Executive in Charge, Howard University
James A. Donaldson, Ph.D., Project Manager, Howard University

*Degree received post-recordation.

Contents

Foreword VII

Acknowledgments IX

Section IV
Burial Descriptions of the New York African Burial Ground, by L. M. Rankin-Hill, J. Gruber, P. Allen, and A. Barrett 1

Appendix A
Research Design Subcommittee Statement and ABG Physical Anthropological Peer Review Panel Report 157

Appendix B
New York African Burial Ground Project Skeletal Analysis Forms 169

Appendix C
Preservation Status Codes for New York African Burial Ground Burials, by S. S. Mahoney and C. Null 219

Foreword

In 1991, during the excavation phase for the construction of the Federal Building now seen at 290 Broadway, New York City, a cemetery was uncovered containing human remains of Africans—most were enslaved, some free—who lived, worked, and died under inhumane conditions in colonial New York. This discovery, the largest bioarchaeological site of its kind, sparked heightened public awareness of an African heritage in the northern states of colonial America. An outcome of this awareness was the public's desire for amending and correcting the history of colonial New York during that period to reflect more accurately the lives and culture of these forgotten Africans and people of African descent and their contributions and roles in economic development. Several initiatives, sponsored by the General Services Administration on behalf of the American people, were launched to accomplish this goal.

The initiative to conduct historical and scientific studies of the remains and artifacts excavated at the site was entrusted to Howard University. There, Dr. Michael L. Blakey, now at the College of William and Mary, designed and implemented a comprehensive, interdisciplinary research program—the New York African Burial Ground Project—to address questions in three main areas: history, archaeology, and skeletal biology. As scientific director of the project, he assembled an international team of scholars, professionals, graduate and undergraduate students, technical staff members, and cultural specialists for various parts of the study.

The New York African Burial Ground: Unearthing the African Presence in Colonial New York serves as the culminating work of this project, reporting the research findings. This multivolume series covers broadly a contextualized historical perspective, details of the archaeological discoveries, and descriptions of the skeletal biology of the unearthed human remains. Each volume documents and validates the lives of African Americans' ancestors who lived and worked in colonial New York. Included in this work are detailed descriptions of the burials excavated, complete with drawings, figures, and tables, as well as a comprehensive appendix of the artifacts found within the burials.

Through the years of this project, membership of the research team changed, but the goal of the project remained constant, that of ensuring that the story of the origins, life, and death of the enslaved Africans of colonial New York would not be absent from the annals of world history.

O. Jackson Cole, Ph.D.
Howard University Executive-in-Charge of the African Burial Ground Project

James A. Donaldson, Ph.D.
Dean, Howard University College of Arts and Sciences

Acknowledgments

It would be impossible to thank all of those in every walk of life who have helped the African Burial Ground Project over the past 12 years. All of those who stood for its preservation and dignity do, however, bear some responsibility for creating the information within this report, and we researchers are deeply indebted to them. We want to thank our supporters: especially the schoolchildren and their teachers. We also thank the churches, the civic and cultural organizations, the grass-roots political organizations, and the hundreds of visitors from around the world who visited our laboratories and offices. Other organizations that deserve recognition are: the Federal Steering Committee, the Schomburg Center; Friends of the African Burial Ground; the Committee of Descendants; Transafrica Forum; Malik Shabazz Human Rights Institute (NYC); Lift Every Voice, Inc. (Los Angeles); and many other organizations and institutions whose members have made this work possible by their moral and political support. Lastly, we would like to acknowledge New York City, State legislators, and their national counterparts, as well as our academic and professional colleagues. We cannot fail to point specifically to the enormous aid of those who stood closest to us for the longest time, including Mayor David Dinkins, State Senator (now Governor) David Paterson, Congressmen Charles Rangel, Jerome Nadler, and Gus Savage, and Senator Alfonse D'Amato. As opportunities are presented, we will continue to recognize every individual effort that has made this project possible.

Many individuals exhibited extraordinary and continuous participation in efforts to protect, elevate, and appreciate the African Burial Ground, without whom there would be neither a National Monument nor our research. Miriam Francis, Adunni Oshupa Tabasi, Dr. Muhammad Hatim, Reverend Herbert Doherty, Eloise Dicks, Mother Franklin, Queen Mother Blakely, Gena Stahlnecker (representing then, Senator David Paterson), Ayo Harrington, Christopher Moore, Renice Goode, Roger Taylor, Mary Lacy Madison, Folana Heidelberg, John Arbogast, Noel Pointer (deceased), Jackie Parker (Sen. Levin's Chief of Staff), Elombe Brath, Howard Wright and many others are deeply appreciated for building this monument. Howard Dodson and Peggy King Jorde, Chairman and Executive Director, respectively, of the Federal Advisory ("Steering") Committee provided the steadfast and wise leadership that focused community concern toward its most productive ends. Later as Project Executive for Memorialization, Ms. Jorde did the groundwork for the ultimate memorial and interpretation of the site for which we are truly grateful.

The Office of Public Education and Interpretation, the branch of the project that provided the vehicle for continuous and growing public involvement in the project by virtue of the outreach of its dedicated and bright public educators who are deeply appreciated, and through the programs designed by its anthropologist Director, Sherrill Wilson, Ph.D. John Milner Associates, who assisted us for several years in the massive early work of the project, especially in New York, we want to thank its principals Dan Roberts and Alan Steinhusen. Looking back, we recognize also the unique contributions of Dale Lanzone and Bob Leuffin of GSA during our most productive negotiations. Thanks especially to Professor Warren Barbour who walked Blakey through the inner workings of contract archaeology as a knowledgeable and trusted confidant during the early negotiations with JMA and GSA.

We want to thank our colleagues at Howard who organized the Ties That Bind ceremonies in 1994 by which the ancestral remains on which we report here were first received into our laboratories, including the

organizers, Eleanor Traylor and Roberta McCleod. We thank Dr. O. Jackson Cole and Dean James Donaldson, who carried out the tireless political and bureaucratic work required to keep Howard University at the center of this project while over time its personnel and funding changed. Others in Washington include Vincent DeForest of the National Park Service (NPS), who was ever present with resources to give, and in New York the founding NPS Supervisor of the National Monument, Tara Morrison, inspires confidence in the work going forward. At the College of William and Mary's Institute for Historical Biology graduate and undergraduate staff involved at the end of this writing project included Grace Turner, Christopher Crain, Renee Ferguson, Jenna Dutcher, and many others who contributed to and benefited from the opportunity to conduct research in the service of the struggle for human rights.

We want especially to take the opportunity to thank those who assisted in the preparation of this report. Even though most are named on the preceding pages, we want to especially thank the staffs of the Howard University Cobb Laboratory, the College of William and Mary Institute for Historical Biology, and the Department of Anthropology at the University of Oklahoma. These individuals conducted research and prepared reports under extraordinarily difficult circumstances, and they did this in the spirit of humane commitment and with high standards. These students, technicians, and senior researchers and directors often sacrificed by working without funding. Although at times there was uncertainty about the security of the project's future, they were nevertheless faithful to the mission for which these volumes mark the culminating success. It is only by virtue of that commitment that we were able to succeed. Among these there were those who devoted many years of their lives working to see that the laboratories and offices functioned for researchers and the public—that the work was done and the data properly organized. These prominently include the office manager of the Cobb Laboratory, Reba Brewington, and its laboratory director, Mark Mack, who devoted at least a decade of their lives to long days of excellence on behalf of the history of the colonial Africans we report on here. All of the writing of this final report and previous drafts relied on their contributions.

The final draft report was prepared starting in January 2003, and the final report unedited version was completed and submitted for transmission to the members of the peer review board near the end of June 2004. In the course of this work, as preparation of the final report versions, involving the merger of submissions from the various authors, was undertaken, all of the database, imaging, and text problems that had not occurred during the writing of the individual chapters and completion of the initial draft versions began to emerge. The smart and dedicated work of Christopher Null of the University of Massachusetts-Amherst and Shannon Mahoney at William and Mary corrected and refined the database and kept the information flowing to the authors. Autumn Barrett, also of the Institute at William and Mary, performed tirelessly and with an extraordinary range of skills as our editorial assistant. All of this was done in addition to their own graduate work and research contributions to the project. Thanks also to Cecelia Moore, administrative assistant, for unflinchingly hard work and dedication to the writing project. Paul Gattis at the University of Oklahoma also contributed to final database development in essential and important ways. Ryan Seltzer of Illinois State University provided key statistical advice. The project has been enormously fortunate to have received the focused attention of these special individuals.

Standing behind us were mentors and senior colleagues without whom there may have been more open fronts of professional warfare than we could have handled. George Armelagos at Emory University and Don Ortner of the Smithsonian Institution have given generously and courageously of their support to this project. As colleagues who shared our goals, Howard Dodson and Leith Mullings worked tirelessly from the very beginning to ensure that our efforts on behalf of this project received a fair airing in New York. We thank the three peer reviewers for useful criticisms of drafts of this manuscript. Finally, we thank our families and friends for giving every means of support imaginable.

Michael L. Blakey, Institute for Historical Biology, Department of Anthropology, College of William and Mary, Williamsburg

Lesley M. Rankin-Hill, Department of Anthropology, University of Oklahoma, Norman

Section IV:

Burial Descriptions of the New York African Burial Ground

L. M. Rankin-Hill, J. Gruber, P. Allen, and A. Barrett

Notes on Burials

Descriptions generally include demographic, infectious disease, nutritional, and chemical sourcing information. Many additional pathologies and characteristics of these burials are described in the Skeletal Biology and Archaeology Databases of the African Burial Ground Project.

Burial 1

Female aged 20–25 years. Cranial and lower-limb periostitis (generalized systemic infection) is present. Enthesopathies are present on the humerus and clavicles. Significant hypertrophy of muscle insertions affects the femora. Osteoarthritis is indicated by eburnation in the shoulder and lipping of the temporomandibular joint. Healed cribra orbitalia indicative of nutritional stress and hypoplasias indicative of childhood stress are present.

Burial 2

Male aged 27–42 years. Individual exhibits evidence of cranial periostitis. Healed cribra orbitalia and cranial porotic hyperostosis indicative of nutritional stress can be observed.

Burial 3

Male aged 25–34.9 years. Mild osteoarthritis affecting the acetabulum can be observed. Healed cribra orbitalia and porotic hyperostosis indicative of nutritional stress are present.



Burial 4

Male aged 30–40 years. Individual exhibits evidence of cranial periostitis. Healed cribra orbitalia and porotic hyperostosis indicative of nutritional stress are present.

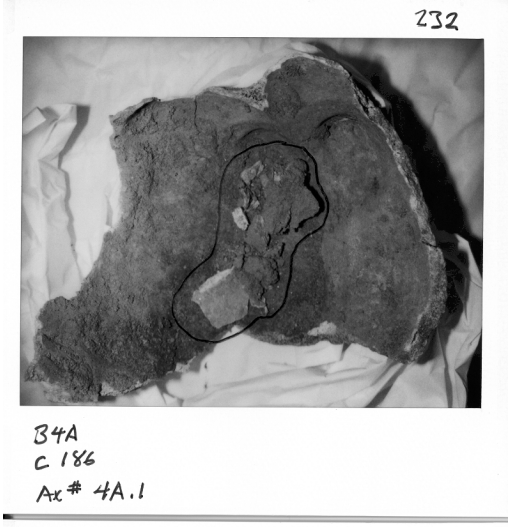

Burial 4.1

Male aged 15–24.9 years. Cranial periostitis can be observed. Healed cribra orbitalia and porotic hyperostosis indicative of nutritional stress are present. (See photo for Burial 4.)



Burial 5

Infant aged .50–1.0 years.

Burial 6

Male aged 25–30 years. Individual has significant muscle-insertion hypertrophy in the lower limbs and an enthesopathy of the left clavicle. Moderate to severe osteoarthritis affects all lower limbs joints and thoracic and lumbar vertebrae. Cervical spondylolysis is present. Periostitis of the lower limbs and possible treponemal disease are present. There is evidence of femoral/tibial bowing associated with rickets. In addition, active cribra orbitalia and diploic expansion indicative of nutritional stress can be observed. Hypoplasia indicators of childhood stress are also present. Trace elemental signature analysis (ESA) clustering is not clearly suggestive of natality. Strontium (Sr) isotope analysis suggests birth in Africa.

Burial 7

Child aged 3–4.9 years. Evidence of cranial periostitis can be observed. Healed cribra orbitalia, porotic hyperostosis, and diploic expansion indicative of nutritional stress are present. Trace ESA clustering not clearly suggestive of natality. Sr isotope analysis suggests birth in the Americas/New York.



Burial 8

Infant aged 0–4.1 years.

Burial 9

Male aged 35–45 years. Individual has periostitis of the lower limbs and multiple enthesopathies in the upper limbs. Mild to severe osteoarthritis affects the elbow, sacroiliac joint, knee, and lumbar synovial joints. Hypoplasia indicators of childhood stress are present. Trace ESA clustering suggests birth in Africa. Sr isotope analysis also suggests birth and migration from Africa.

Burial 10

Male aged 40–45 years. Periostitis of the lower limbs can be observed. Osteoarthritis affects many axial and appendicular joints. Osteophytosis of the cervical vertebrae and lumbar/sacral fusion is also present. Significant muscle-insertion hypertrophy is present throughout the skeleton, and there are clavicular syndesmophytes. Femoral/tibial bowing indicative of rickets and hypoplasia indictors of childhood stress are present.

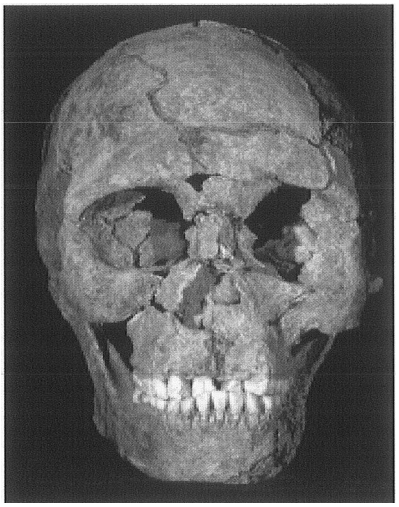

Burial 11

Male aged 30–40 years. Individual has multiple enthesopathies with muscle-insertion hypertrophy. Vertebral osteophytosis is present. Healed cribra orbitalia indicative of nutritional stress can be observed. Hypoplasia indicators of childhood stress are also present.

Burial 12

Female aged 35–45 years. Individual has periostitis of the lower and upper limbs and crania. Femoral/tibial bowing is indicative of rickets. Significant biomechanical work stress is indicated with muscle-insertion hypertrophies and enthesopathies throughout the skeleton. Osteoarthritis affects the axial and appendicular joints. Thoracic spondylolysis is also present. Healed cribra orbitalia and porotic hyperostosis indicative of nutritional stress can be observed.

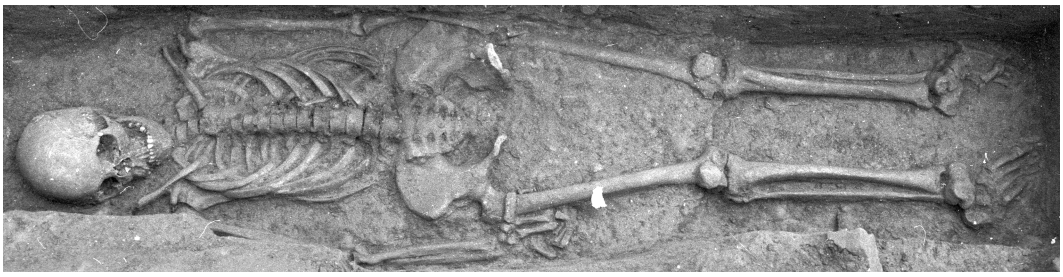

Burial 13

Subadult of indeterminate age.

Burial 14

Infant aged 0–3.0 years. Cranial periostitis and meningitis can be observed.

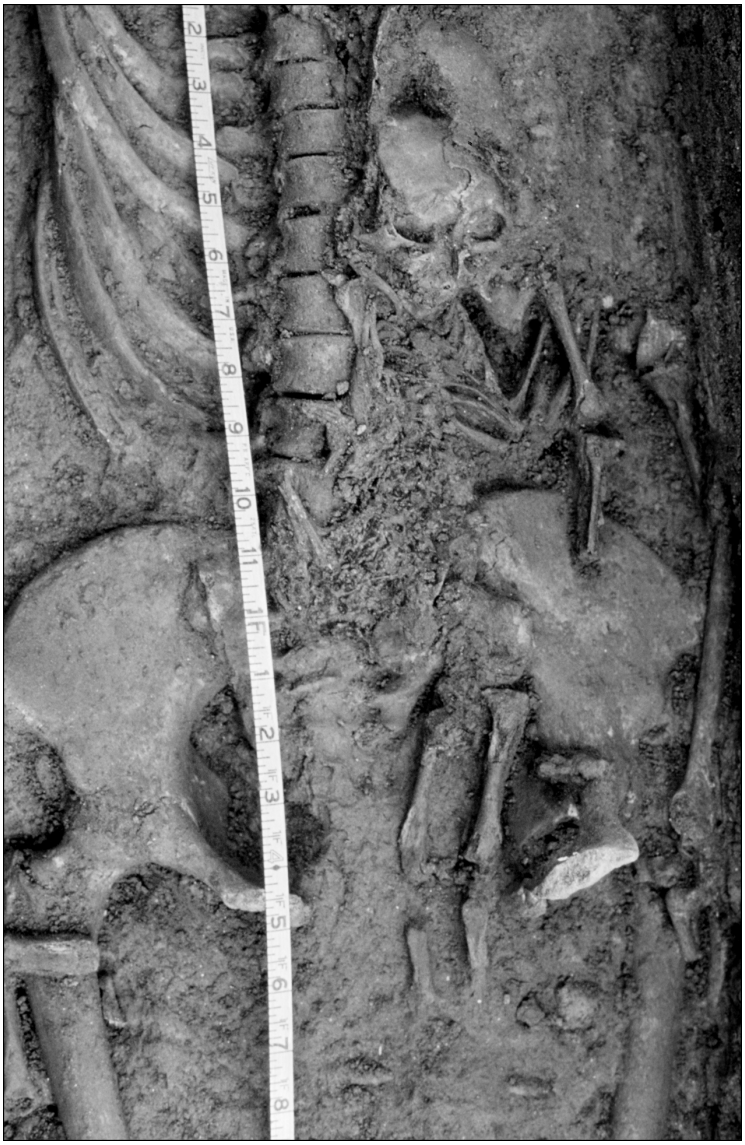

Burial 15

Child/adolescent aged 11–18 years.

Burial 16

Female aged 50–60 years. There is evidence of periostitis of the lower limbs. Femoral/tibial bowing associated with rickets can be observed. Significant muscle-insertion hypertrophies in the upper and lower limbs are present, with moderate to severe osteoarthritis affecting the knee and ankle joints. Cervical osteophytosis and lumbar ankylosis are observable in the vertebrae. Healed cribra orbitalia indicative of nutritional stress can be observed.

Burial 17

Child aged 4–6 years. Healed cribra orbitalia and expanded diploe are indicative of nutritional stress. Femoral/tibial bowing associated with rickets is also present.

Burial 18

Female aged 35–45 years. Individual has periostitis of the lower limbs and crania and possible treponemal disease. Significant hypertrophy of the femoral gluteal insertion and a moderate degree of osteoarthritis affect the foot and ankle.



Burial 19

Subadult of indeterminate age.

Burial 20

Male aged 45–50 years of age. Individual has periostitis of the lower limbs and significant muscle-insertion hypertrophies. A moderate degree of osteoarthritis of the lower limbs and of the hand is present.

Burial 21

Subadult of indeterminate age.



Burial 22

Child aged 2.5–4.5 years. Periostitis of the lower and upper limbs can be observed. Trace ESA clustering suggests birth in Africa; however, Sr isotope analysis suggests birth probably in the Americas/New York.

Burial 23

Male aged 25–35 years. Periostitis of the lower limbs and possible treponemal disease can be observed. Significant hypertrophies are present in the upper limbs and humeral enthesopathy. Lumbar osteophytosis and Schmorl's nodes are present. Hypoplasia indicators of childhood stress can be observed. Trace ESA suggests birth in Africa. Sr isotope analysis also suggests birth in Africa.

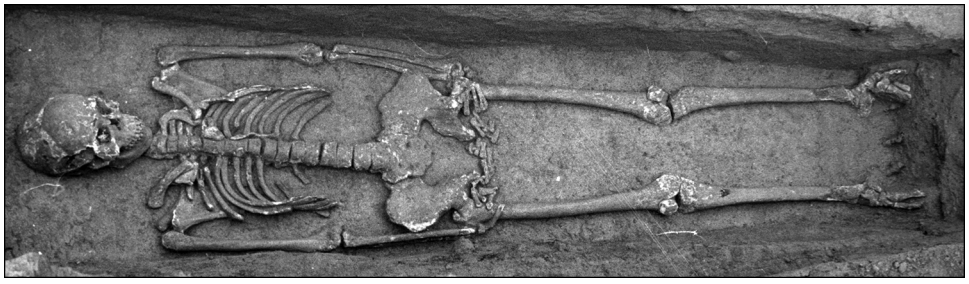

Burial 24

Child aged 3–6 years.



Burial 25

Female aged 20–24 years. Enthesopathies of the brachialis insertions on the ulnae are present.

Burial 26

Child/adolescent aged 8–12 years.

Burial 27

Infant aged 1.40–2.80 years. Diploic expansion indicative of nutritional stress can be observed. Hypoplasia and hypocalcification indicators of childhood stress are present.

Burial 28

Subadult of indeterminate age.



Burial 29

Male aged 35–45 years. Periostitis of the lower limbs and a slight degree of osteoarthritis affecting the tarsal bones are present.

Burial 30

Child aged 7–11 years. Periostitis of the lower limbs can be observed. Hypoplasia indicators of childhood stress are present.

Burial 31

Unsexed aged 14–16 years. Individual had active periostitis of the lower limbs at time of death. There is evidence of anterior-posterior bowing associated with rickets, as well as possible treponemal disease.

Burial 32

Male aged 50–60 years. Individual has cranial periostitis and osteomyelitis of the lower limbs. There is evidence of multiple enthesopathies in the ulnae and myositis ossificans of the ribs. There is also moderate to severe osteoarthritis affecting the axial and appendicular skeleton. Vertebral osteophytosis and thoracic Schmorl's nodes are also present. Healed cribra orbitalia and expanded diploe indicative of nutritional stress can be observed.

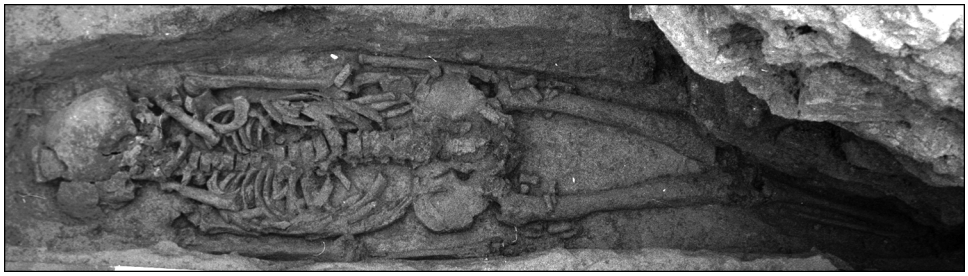

Burial 33

Adult of indeterminate age and sex.

Burial 34

Adult of indeterminate age and sex.

Burial 35

Child aged 8–10 years. Individual has healed cribra orbitalia and expanded diploe indicative of nutritional stress, and hypoplastic indicators of childhood stress are also present. Trace ESA clustering is not clearly suggestive of natality. Sr isotope analysis suggests birth probably in the Americas/New York.

Burial 36

Female of indeterminate age. This individual has periostitis of the lower limbs. Femoral/tibial bowing indicative of rickets can be observed. Significant muscle-insertion hypertrophy of the tibiae are present.



Burial 37

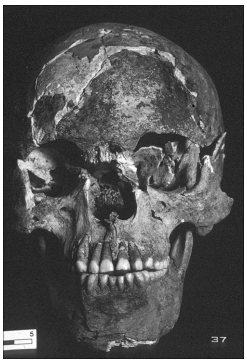

Male aged 45–55 years. Individual has periostitis of the lower limbs and crania. There are enthesopathies in the upper limbs, and significant muscle-insertion hypertrophy is present throughout the skeleton. Moderate to severe osteoarthritis affects the axial and appendicular joints. Osteophytosis, lumbar spondylolysis, and Schmorl's nodes are also present in the vertebrae. Hypoplastic indicators of childhood stress are present.



Burial 38

Female aged 20–25 years. Hypoplasias indicative of childhood stress are present.

Burial 39

Child aged 5–7 years. This individual has periostitis of the lower and upper limbs. Eburnation, erosion, and lipping of the first cervical vertebra and occipital condyles are present. Distortion of the joint and extension of the surface suggest posterior displacement of the cervical onto the occipital squama. Enthesopathies are present on the humeri and ulnae. Healed cribra orbitalia and porotic hyperostosis indicative of nutritional stress and hypoplastic indicators of childhood stress are present. Trace ESA clustering suggests birth in the Americas/New York. Sr isotope analysis also suggests birth in the Americas/New York.

Burial 40

Female aged 50–60 years. Individual has periostitis of the lower limbs and crania. Femoral/tibial bowing associated with rickets is present. Myositis ossificans on the tibiae and ribs with significant muscle-insertion hypertrophy can be observed throughout the skeleton. Moderate to severe osteoarthritis affects axial and appendicular joints. Osteophytosis is also present in the vertebrae.

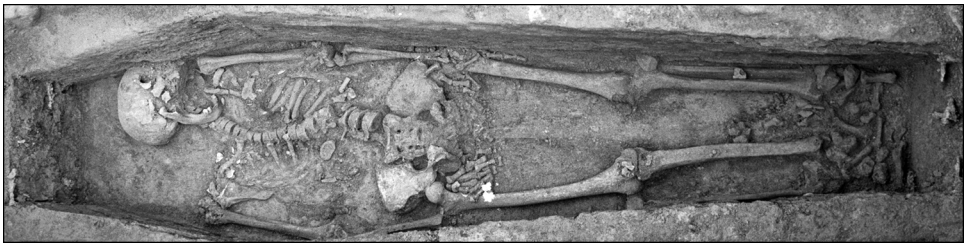

Burial 41

Adult of indeterminate age and sex.

Burial 42

Infant aged 0–2.0 years. Periostitis of the lower and upper limbs is evident.

Burial 43

Child aged 2.5–4.5 years. Diploic expansion indicative of nutritional stress is present. Trace ESA clustering is not clearly suggestive of natality.

Burial 44

Child aged 3–9 years.

Burial 45

Child aged 2.5–4.5 years. Evidence of meningitis is observable. Femoral/tibial bowing associated with rickets and healed cribra orbitalia indicative of nutritional stress are present. Hypoplastic indicators of childhood stress are observable. Trace ESA clustering suggests birth in the Americas/New York.

Burial 46

Female of indeterminate age. Individual has periostitis of the lower and upper limbs. Moderate osteoarthritis affects the hip and knees.

Burial 47

Male aged 35–45 years. Periostitis of the lower limbs and crania can be observed. Multiple enthesopathies and moderate osteoarthritis are present. Trace ESA clustering is not clearly suggestive of natality, although third-molar clustering with B2 and low Pb concentration suggest early life in Africa. However, low Sr isotope values indicate birth possibly in the Caribbean.

Burial 48

Adult of indeterminate age and sex.

Burial 49

Female aged 40–50 years. There is evidence of periostitis of the lower limbs and crania. Significant muscle-insertion hypertrophy of the tibiae and femora are present. Mild osteoarthritis affects the upper-limb joints. Healed cribra orbitalia and porotic hyperostosis indicative of nutritional stress can be observed. Hypoplasia and hypocalcification indicators of childhood stress are present.

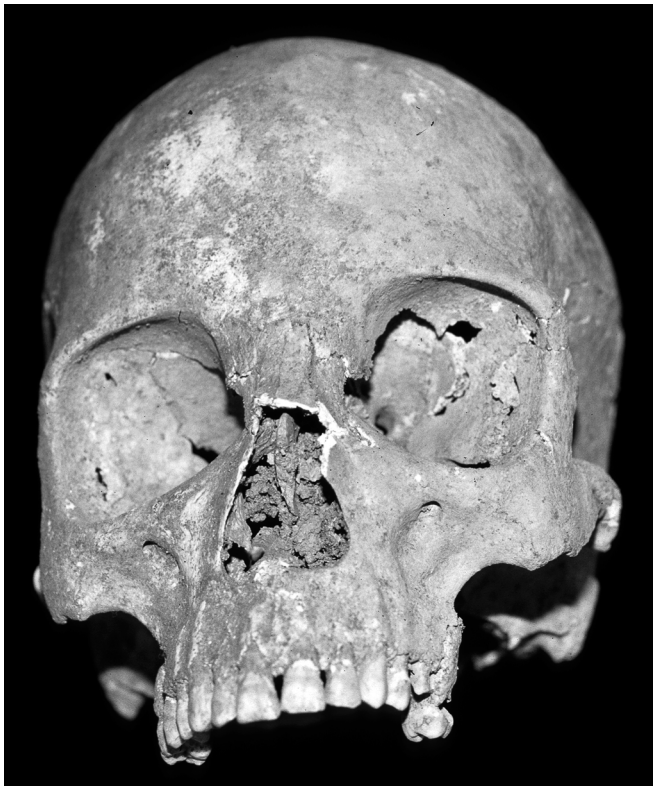

Burial 50

Child of indeterminate age.

Burial 51

Female aged 24–32 years. Individual has periostitis of the lower limbs and crania. There is evidence of biomechanical work stress, with significant muscle-insertion hypertrophy, primarily in the upper limbs, and enthesopathies of the brachialis insertions on the ulnae. Moderate osteoarthritis is present throughout the axial and appendicular joints. Vertebral osteophytosis and osteochondritis dissicans of the knee joints are also present. Diploic expansion indicative of nutritional stress and hypoplasia and hypocalcification indicators of childhood stress are present.



Burial 52

Age and sex indeterminate.

Burial 53

Infant aged .25–.75 years. Periostitis of the upper and lower limbs can be observed.

Burial 54

Adult of indeterminate age and sex.

Burial 55

Child aged 3–4.9 years. Individual has periostitis of the lower and upper limbs and crania. Healed cribra orbitalia and diploic expansion are indicative of nutritional stress. Hypoplasia and hypocalcification indicators of childhood stress are present. Trace ESA clustering is not clearly suggestive of natality.

Burial 56

Female aged 30–34 years. Individual has significant muscle-insertion hypertrophies and enthesopathies throughout the skeleton. Moderate osteoarthritis affects multiple axial and appendicular joints. Lumbar Schmorl's nodes are also present. Healed cribra orbitalia and porotic hyperostosis indicative of nutritional stress can be observed. Hypocalcification indicators of childhood stress are present.

Burial 57

Infant aged .88–2.16 years. Hypoplasia and hypocalcification indicators of childhood stress are present.

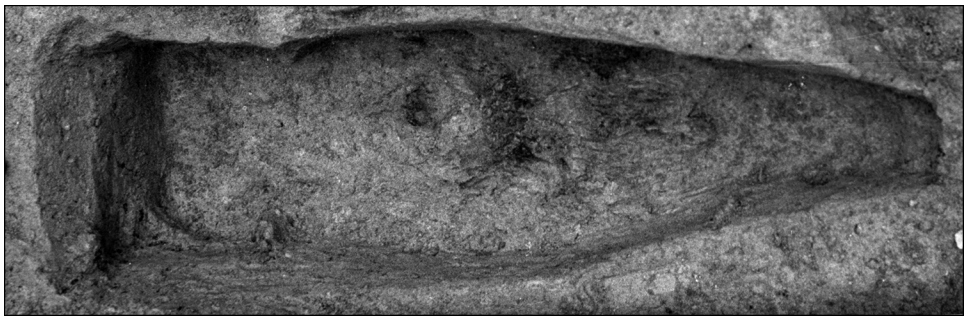

Burial 58

Child aged 3.5–5.5 years. Periostitis of the lower and upper limbs is present.

Burial 59

Infant aged 0–.25 years.



Burial 60

Infant aged .25–.75 years.

Burial 61

Child of indeterminate age.



Burial 62

Indeterminate age and sex.

Burial 63

Male aged 35–45 years. There is evidence of periostitis of the lower and upper limbs. There are enthesopathies and significant muscle-insertion hypertrophy throughout the skeleton. A mandibular tori is also present. Myositis ossificans is found on the thoracic vertebrae, ribs, and left pubis. Moderate to severe osteoarthritis affects the axial and appendicular skeleton. Osteophytosis and lumbar Schmorl's nodes are present in the vertebrae. Porotic hyperostosis and diploic expansion indicative of nutritional stress can be observed.

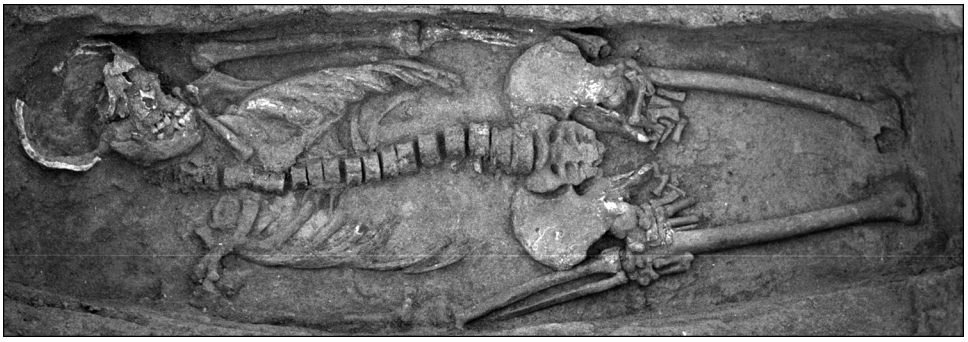

Burial 64

Infant aged .38–.88 years. Cranial periostitis with active cribra orbitalia, porotic hyperostosis, and diploic expansion indicative of nutritional stress can be observed.

Burial 65

Perinatal.

Burial 66

Infant aged 0–0.16 years.

Burial 67

Male aged 40–50 years. Individual has periostitis of the lower and upper limbs. Muscle-insertion hypertrophy is present throughout the skeleton, with enthesopathies of the brachialis insertions on the ulnae. Myositis ossificans is found on the thoracic vertebrae and ribs. Moderate to severe osteoarthritis affects axial and appendicular joints. Lumbar Schmorl's nodes are also present.

Burial 68

Male aged 21–25 years. A slight degree of osteoarthritis is present, with a robust femora linea aspera. Sr isotope analysis (of dentin only) suggests birth probably in Africa.



Burial 69

Male aged 25–25 years. There is evidence of periostitis of the lower limbs and possible treponemal disease. Significant muscle-insertion hypertrophies and enthesopathies are present throughout the skeleton. Mild to moderate osteoarthritis affects joints in the upper and lower limbs. Femoral/tibial bowing associated with rickets can be observed.

Burial 70

Male aged 35–45 years. There is evidence of periostitis of the lower and upper limbs, saber shins, and possible treponemal disease. There are multiple enthesopathies and significant muscle-insertion hypertrophies, primarily in the upper limbs. There is evidence of myositis ossificans in the lumbar vertebrae and ribs with lumbar Schmorl's nodes; all limb joints have at least mild osteoarthritic changes. Femoral/tibial bowing associated with rickets can be observed.

Burial 71

Female aged 25–34.9 years. Individual has periostitis of the lower limbs and crania. Clavicular syndesmophytes, myositis ossificans on the thoracic vertebrae, and multiple significant hypertrophies of the lower limbs are present. At least mild osteoarthritis affects most joints, with moderate to severe changes in the lower limbs. Osteophytosis and lumbar Schmorl's nodes are also present.

Burial 72

Subadult aged 1–2 years. There is evidence of meningitis, diffuse bone loss, cranial periostitis, and lower-limb periostitis. Hypoplasia and hypocalcification indicators of childhood stress are present.

Burial 73

Female aged 20–30 years. Several muscle-insertion sites in the upper limbs exhibit significant hypertrophy. Moderate osteoarthritis affects the hip and vertebrae. Cervical osteophytes are also present. Diploic expansion indicative of nutritional stress can be observed.

Burial 74

Empty shaft.

Burial 75

Perinatal.

Burial 76

Male, age unknown. Individual has periostitis of the lower limbs. Several enthesopathies and significant insertion hypertrophies are found throughout skeleton. Myositis ossificans of the femur and moderate to severe osteoarthritis affects several of the appendicular joints. Active, healing, and healed porotic hyperostosis indicative of nutritional stress can be observed.

Burial 77

Infant aged .67–1.30 years. Hypoplasia and hypocalcification indicative of childhood stress are present.



Burial 78

Age 16–19. Sex indeterminate. Cranial periostitis is present.

Burial 79

Infant aged .25–.75 years.

Burial 80

Subadult of indeterminate age.



Burial 81

Female of indeterminate age. Individual has femoral/tibial bowing associated with rickets. Ulnar enthesopathies with mild to moderate osteoarthritis affecting the lower limbs are present.

Burial 82

Female aged 18–25 years. Individual has cranial periostitis. Osteoarthritis affects the cervical and thoracic vertebrae; cervical osteophytosis is also present. Healed cribra orbitalia indicative of nutritional stress and hypoplastic indicators of childhood stress can be observed.

Burial 83

Subadult aged .00–15.00 years.

Burial 84

Female aged 17–21.0 years. Evidence of osteomyelitis is observable. Significant osteoarthritic lipping of the lumbar vertebrae is present.

Burial 85

Infant aged .25–.75 years.



Burial 86

Child aged 6–8 years. Individual has periostitis of the lower and upper limbs and crania. Diploic expansion is indicative of nutritional stress.

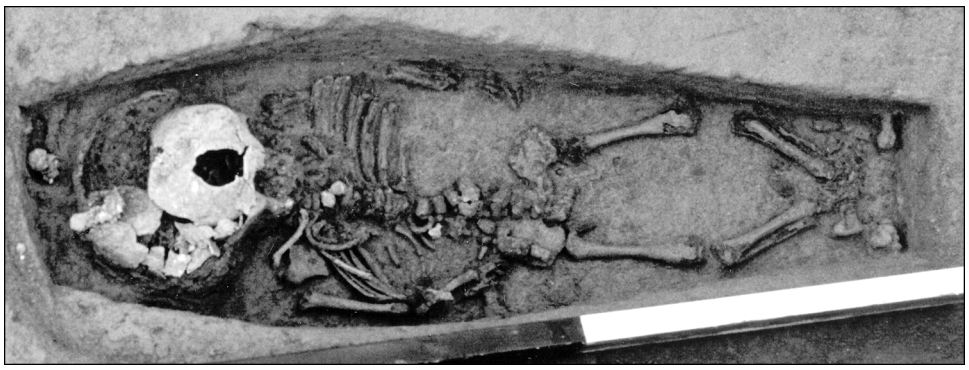

Burial 87

Child aged 4–6 years. Diploic expansion indicative of nutritional stress can be observed.



Burial 88

Age and sex indeterminate.



Burial 89

Female aged 50–60 years. There is evidence of enthesopathies at more than 20 muscle insertions and significant hypertrophy at many others. Mild to severe osteoarthritis affects nearly all of the joints examined. Osteophytosis is present in all three vertebral regions.

Burial 90

Female aged 35–40 years. Significant biomechanical work stress is evidenced by numerous enthesopathies and muscle-insertion hypertrophy throughout the skeleton. Mild osteoarthritis affects the shoulder, elbow, and thoracic vertebrae. Schmorl's nodes are present in the lumbar vertebrae. Expanded diploe and healed porotic hyperostosis indicative of nutritional stress and femoral/tibial bowing associated with rickets are observable. Hypoplastic indicators of childhood stress are present.

Burial 91

Infant aged .67–1.3 years of age. Periostitis of the lower and upper limbs can be observed. Diploic expansion indicative of nutritional stress and hypoplasia and hypocalcification indicators of childhood stress are present.

Burial 92

Indeterminate age and sex. (Photo includes Burial 92 and Burial 95.)

Burial 93

Adult of indeterminate age and sex.

Burial 94

Subadult of indeterminate age. No in situ photograph available. Combined with Burial 96; remains are not identifiable in photograph.

Burial 95

Child aged 7–12 years. Enthesopathy at the insertions surrounding the intertubercular groove of the left humerus, and the brachialis insertion of the ulnae show significant hypertrophy. Mild lipping of the zygopophyseal joints affects all vertebral regions.

Burial 96

Male aged 16–18 years. Mild to moderate hypertrophies of several muscle insertions are present. Periarticular resorptive foci affect the acetabula. Individual has hypoplastic indicators of childhood stress.

Burial 97

Male aged 40–50 years. There is evidence of periostitis of the lower and upper limbs. There are enthesopathies at 20 different locations, and significant muscle-insertion hypertrophies are present throughout the skeleton. Mild to severe osteoarthritis affects many of the axial and appendicular joints. There is carpal-bone fusion in the right wrist. In the vertebral column, thoracic and cervical Schmorl's nodes and lumbar spondylolysis are present. Healed porotic hyperostosis and diploic expansion indicative of nutritional stress can be observed. Hypoplastic indicators of childhood stress are present.



Burial 98

Infant aged 1.0–2.0 years.



Burial 99

Child aged 6–10.0 years.

Burial 100

Subadult of indeterminate age.



Burial 101

Male aged 26–35 years. Individual has cranial and lower-limb periostitis, saber shins, and possible treponemal disease. Enthesopathies of the brachialis insertions of the ulnae, myositis ossificans in the ribs, and a few muscle-insertion sites with significant hypertrophy can be observed. Mild to severe osteoarthritis affects the axial and appendicular skeleton. Schmorl's nodes and thoracic spondylolysis are also present. A slight amount of nutritional stress can be observed. Hypoplasia and hypocalcification indicators of childhood stress are present in the dentition. Trace ESA clustering is not clearly suggestive of natality. Sr isotope analysis suggests birth in the Americas/New York, while lead levels are intermediate of African and colonial American signatures.



Burial 102

Infant aged 1.33–2.67 years. Hypoplasia and hypocalcification indicators of childhood stress are present.

Burial 103

Subadult of indeterminate age.

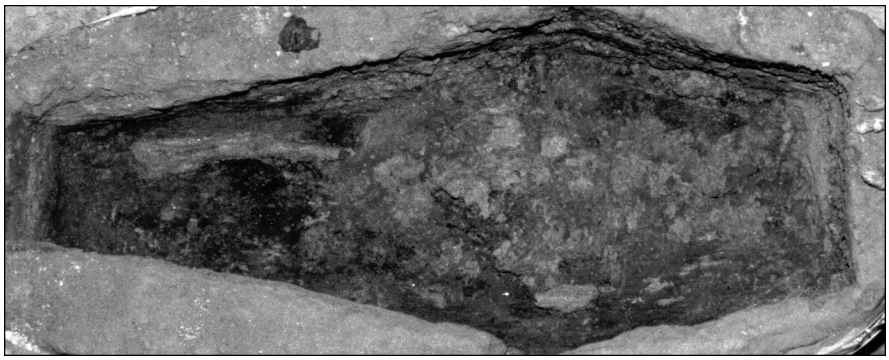

Burial 104

Female aged 30–40 years. There is evidence of lower-limb periostitis, with numerous enthesopathies and significant muscle-insertion hypertrophy. Moderate to severe osteoarthritis affects many axial and appendicular joints. Osteophytosis is present on the cervical and lumbar vertebrae. Diploic expansion indicative of nutritional stress can be observed.

Burial 105

Male aged 35–45 years. Individual has periostitis of the lower and upper limbs. There is significant hypertrophy of the linea aspera and the biceps brachii insertions of the radii. Mild osteoarthritis affects several appendicular joints. Thoracic and lumbar Schmorl's nodes are also present.

Burial 105.1

Female aged 35–45 years (no photograph). Mild osteoarthritis of the hand and knee joints is present.

Burial 106

Female aged 25–35 years. Evidence of lower- and upper-limb periostitis can be observed. There is femoral/tibial bowing associated with rickets. Well-developed femoral linea aspera can be observed. Trace ESA clustering is not clearly suggestive of natality. Sr isotope analysis suggests birth in Africa.

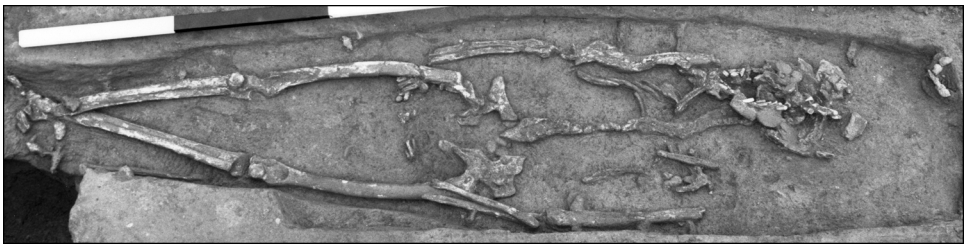

Burial 107

Female aged 35–40 years. Individual has enthesopathies or significant hypertrophy of many muscle insertions throughout the skeleton. Mild to moderate osteoarthritis affects most axial and appendicular joints. Osteophytes, Schmorl's nodes, and lumbar spondylolysis of the vertebrae are present. Diploic expansion indicative of nutritional stress can be observed. Hypoplastic indicators of childhood stress are present.

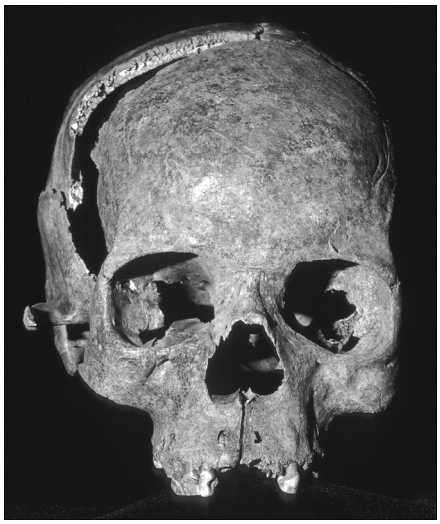

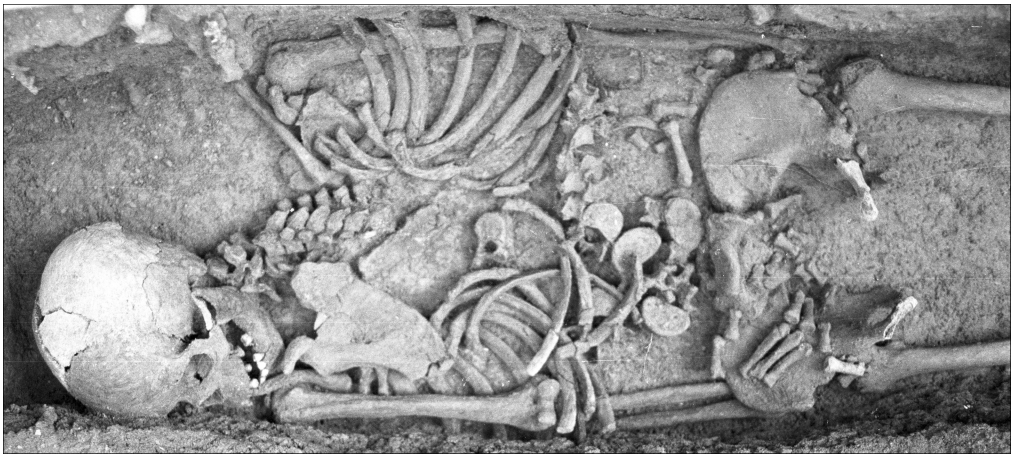

Burial 108

Infant aged .25–.75 years.

Burial 109

Infant aged .67–1.33 years. Hypoplasia and hypocalcification indicate childhood stress.

Burial 110

Infant aged -.17–.17 years.

Burial 111

Infant aged .67–1.33 years. Hypoplasias and hypocalcifications indicate childhood stress.

Burial 112

Infant aged .25–.75 years.

Burial 113

Adult of indeterminate age.

Burial 114

Male aged 45–50 years. Individual has upper and lower-limb periostitis. There is evidence of multiple enthesopathies and significant and muscle-insertion hypertrophies in the upper limbs. The linea aspera of the femora are well developed. Mild osteoarthritis affects several upper- and lower-limb joints, with moderate to severe changes in the elbow and wrist. Osteophytosis is present on cervical, thoracic, and lumbar vertebrae. Healed porotic hyperostosis and diploic expansion indicative of nutritional stress can be observed. Hypoplasias and hypocalcifications indicate childhood stress. Low Sr isotope values suggest birth possibly in the Caribbean.

Burial 115

Female aged 25–34.9 years. Lower limb and cranial periostitis are present. Enthesopathic attachments are present on humeri, ulnae, and clavicles. Mild osteoarthritis affects the shoulder, elbow, hand, and knee. Hypoplasias and hypocalcification indicate childhood stress. Trace ESA clustering suggests birth in Africa. Sr isotope analysis suggests birth probably in the Americas/New York.

Burial 116

Male aged 45–55 years. There is evidence of lower-limb periostitis and possible treponemal disease. Several enthesopathies of the clavicles and ulnae are observable. Eburnation affects the proximal and distal articulations of the tibiae. Osteophytes are present on the lumbar vertebrae.

Burial 117

Perinatal. There is observable periostitis of lower and upper limbs throughout the skeleton.

Burial 118

Adult of indeterminate age.

Burial 119

Male aged 35–45 years. Occipital enthesopathy is present, and periarticular resorptive foci are present at the acetabula.

Burial 120

Female aged 25–34 years. There is evidence of lower-limb periostitis and of well-developed deltoid tuberosities of the humeri. Diploic expansion indicative of nutritional stress can be observed. Hypoplasias and hypocalcifications indicate childhood stress.

Burial 121

Child aged 2.5–4.5 years. Diploic expansion indicative of nutritional stress can be observed. Hypoplasia indicators of childhood stress are present.

Burial 122

Female aged 18–20.0 years. Individual has cranial and lower upper limb periostitis, several muscle insertions with significant hypertrophy throughout the skeleton, and enthesopathies of the humerus and clavicles. Mild to severe osteoarthritis affects axial and appendicular joints. There is femoral/tibial bowing associated with rickets. Healed porotic hyperostosis, cribra orbitalia, and diploic expansion indicative of nutritional stress can be observed.

Burial 123

Infant aged .67–1.33 years. Hypoplasia and hypocalcification indicate childhood stress.

Burial 124

Adult of indeterminate age. Lower-limb periostitis can be observed. Diploic expansion indicative of nutritional stress is present.

Burial 125

Indeterminate age and sex. Evidence of lower-limb periostitis is present. Severe osteoarthritis affects the foot and ankle.

Burial 126

Child aged 3.5–5.5 years. Healed porotic hyperostosis and diploic expansion indicative of nutritional stress can be observed. Hypoplasias indicative of childhood stress are present. Trace ESA clustering is not clearly suggestive of natality.

Burial 127

Infant aged .67–1.33 years. Hypoplasias indicative of childhood stress are present.



Burial 128

Subadult of indeterminate age.

Burial 129

Indeterminate age and sex.

Burial 130

Infant aged 1.0–2.0 years. Individual has healed cribra orbitalia indicative of nutritional stress; hypoplasia and hypocalcification indicators of childhood stress are also present.

Burial 131

Subadult, age unknown.

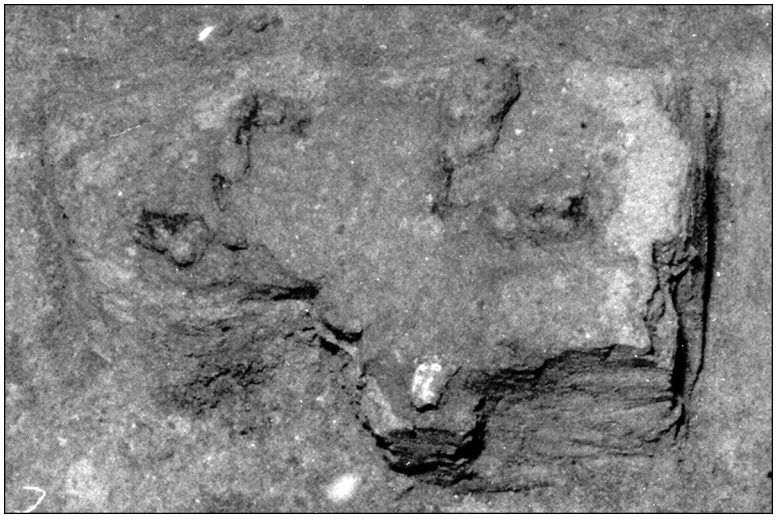

Burial 132

Male aged 25–30 years. Individual has lower-limb periostitis. The skeleton exhibits syndesmophytes at the rhomboid ligament attachment of the clavicle. Moderate osteoarthritis affects the hip.

Burial 133

Infant aged 1.0–2.0 years. Lower- and upper-limb periostitis can be observed. Hypoplasia and hypocalcification indicators of childhood stress are present.

Burial 134

Female aged 40–50 years. Individual has lower-limb periostitis and several significant hypertrophies of muscle insertions on the humerus and femur. Moderate to severe osteoarthritis affects the ankle, foot, and shoulder. There is ankylosis of the sacroiliac joints.

Burial 135

Male aged 30–40 years. Lower-limb periostitis is observable. There are many enthesopathies and significant muscle-insertion hypertrophies throughout the skeleton. Osteoarthritis affects axial and appendicular joints. Osteophytes and Schmorl's nodes are also present. Hypoplasias evidence childhood stress. Healed porotic hyperostosis indicative of nutritional stress can be observed.

Burial 136

Subadult of indeterminate age.

Burial 137

Adult of indeterminate sex, aged 25–35 years.

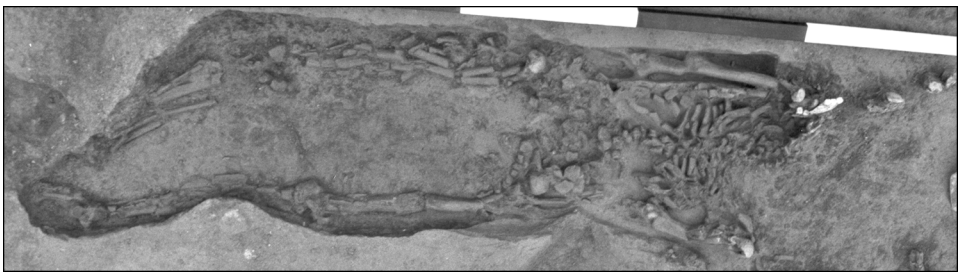

Burial 138

Child aged 3–4.9 years. This individual exhibits healed porotic hyperostosis and diploic expansion. Hypoplasia and hypocalcification indicators of childhood stress are present. Trace ESA clustering suggests birth in the Americas/New York. Sr isotope analysis also suggests birth in the Americas/New York.

Burial 139

Empty shaft. (No photograph.)

Burial 140

Empty shaft. (No photograph.)

Burial 141

Empty shaft. (No photograph.)

Burial 142

Female aged 25–30 years. Present are significant hypertrophies of single insertions of the ilia, humeri, and scapulae and severe osteoarthritis of the hip and knee . Hypocalcification indicators of childhood stress are present. (Photo includes subadult Burials 144 and 149.)



Burial 143

Child aged 6–10 years.

Burial 144

Infant aged 0–.17 years.

Burial 145

Empty Shaft.



Burial 146

Infant aged 0–.49 years.



Burial 147

Male aged 55–65 years. Periostitis is present in the lower and upper limbs, and there is possible treponemal disease. Most of the muscle insertions examined show enthesopathies or significant hypertrophy. Moderate to severe osteoarthritis affects all of the major joint complexes. Osteophytes are observable in the cervical, thoracic, and lumbar regions of the spine. Healed cribra orbitalia and diploic expansion indicative of nutritional stress can also be observed. Hypoplasias indicative of childhood stress are present.

Burial 148

Unsexed individual aged 12–15 years. There is evidence of femoral/tibial bowing associated with rickets. Cranial synostosis can also be observed.



Burial 149

Infant aged .50–1.0 years.



Burial 150

Female aged 20–28 years. There is evidence of cranial and lower- and upper-limb periostitis. Several muscle insertions in the upper limb have significant hypertrophy. Mild to severe osteoarthritis affects many appendicular joints and the lumbar vertebrae. Healed cribra orbitalia indicative of nutritional stress can be observed. Hypoplasia and hypocalcification indicators of childhood stress are present.

Burial 151

Male aged 35–45 years. Individual has syndesmophytes at the rhomboid attachment on the clavicle and several significant hypertrophies in the upper limb. Mild osteoarthritis affects the axial and appendicular skeleton, with moderate changes in the lumbar vertebrae and elbow. Osteophytosis occurs throughout the vertebral column, and Schmorl's nodes are present on the sacral body and inferior end plate of L5. There is evidence of dislocation at the left temporomandibular joint and osteochondritis dissicans at the knee. Healed porotic hyperostosis and diploic expansion indicative of nutritional stress can also be observed.

Burial 152

Age and sex indeterminate.

Burial 153

Female of indeterminate age. Hypoplasias indicative of childhood stress are present. Individual has lumbar osteophytosis.

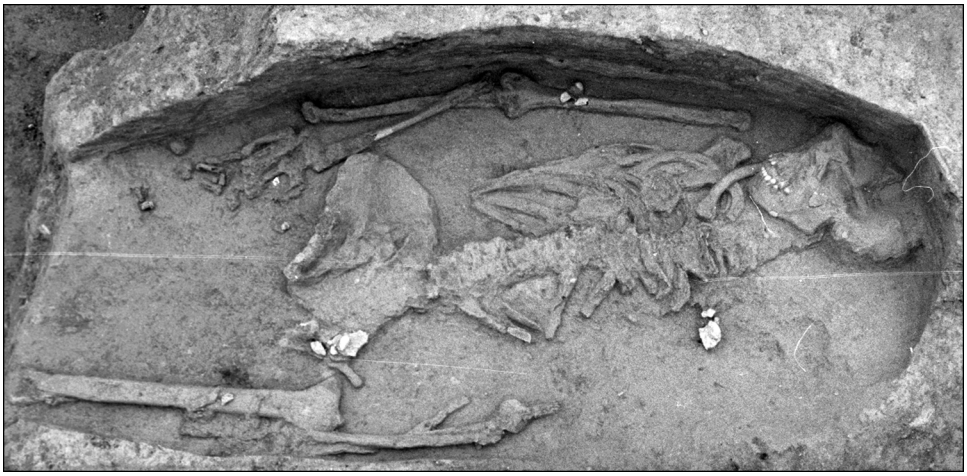

Burial 154

Female aged 25–29 years. This individual has lower- and upper-limb periostitis and multiple enthesopathies and hypertrophies of muscle insertions, predominantly in the upper limb. Mild to moderate osteoarthritis affects the axial and appendicular skeleton. Osteophytes and Schmorl's nodes are also present. Healed porotic hyperostosis and diploic expansion indicative of nutritional stress can be observed.

Burial 155

Adult of indeterminate age and sex. Possible treponemal disease is observable.



Burial 156

Female of indeterminate age. This individual has lower-limb periostitis, multiple enthesopathies, and significant hypertrophies. Mild to moderate osteoarthritis affects all joint complexes examined. There is evidence of femoral/tibial bowing associated with rickets.

Burial 157

Female of indeterminate age and sex. Individual has significant hypertrophy of the gluteal muscle attachments on the femora.

Burial 158

Male aged 20–30 years. Individual has lower-limb and cranial periostitis. Multiple enthesopathies and significant muscle-insertion hypertrophy are present throughout the skeleton. Mild to severe osteoarthritis affects axial and appendicular joints. Cervical osteophytes and Schmorl's nodes are present. Healed porotic hyperostosis and cribra orbitalia indicative of nutritional stress can also be observed. Hypoplasia and hypocalcification indicators of childhood stress are also present.



Burial 159

Female aged 25–34.9 years. Evidence of meningitis with cranial and lower- and upper-limb periostitis is present. Multiple enthesopathies and significant muscle-insertion hypertrophies are present, primarily in the upper limbs. Mild to moderate osteoarthritis affects axial and appendicular joints. Hypoplasia and hypocalcification indicators of childhood stress are present.

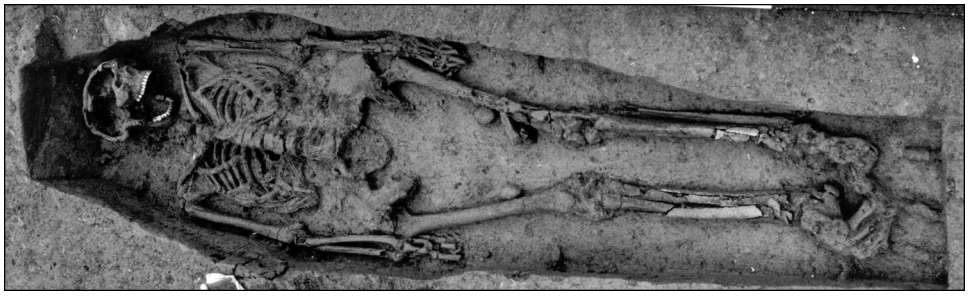

Burial 160

Child aged 3.5–5.5 years. Hypoplasia and hypocalcification indicators of childhood stress are present. Trace ESA clustering suggests birth in the Americas/New York.

Burial 161

Subadult of indeterminate age.

Burial 162

Male aged 35–45 years. Osteophytes of the thoracic vertebrae are present.

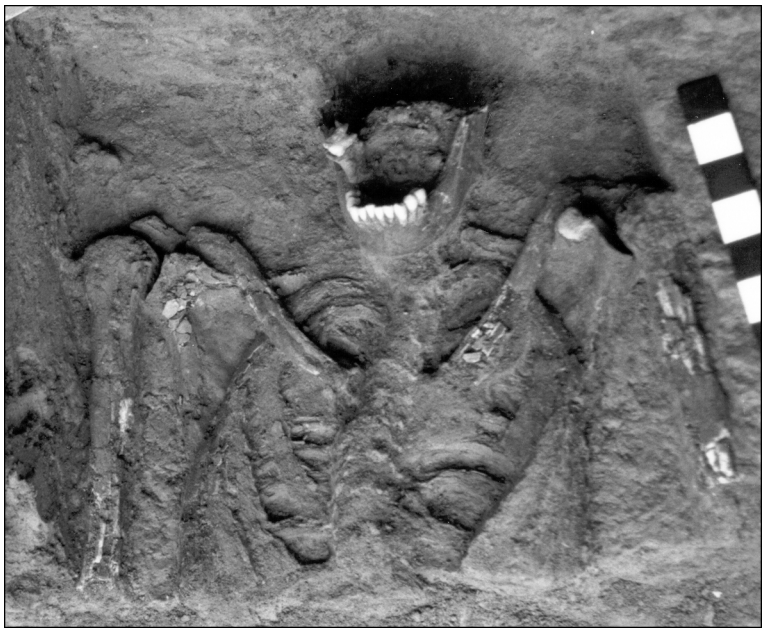

Burial 163

Male aged 18–24 years. Significant hypertrophy of the gluteal-muscle attachments of the femora is present.



Burial 164

Child/adolescent aged 8–13 years. The skeleton has significant hypertrophy of the gluteal muscle attachments of the femora and the insertions of the intertubercular grooves on the humeri.

Burial 165

Adult of indeterminate age. There is observable lower-limb periostitis. Healed porotic hyperostosis, cribra orbitalia, and diploic expansion indicative of nutritional stress are present.

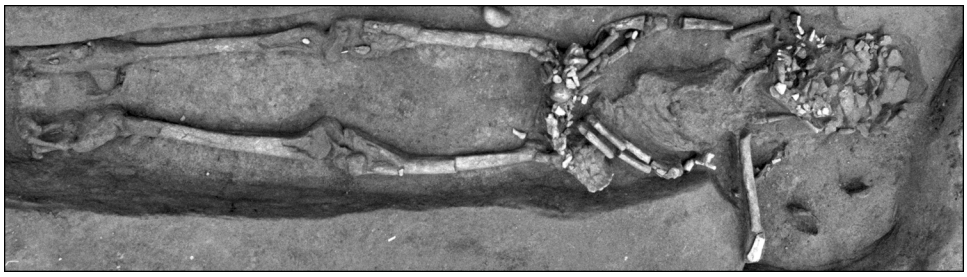

Burial 166

Infant aged .50–1.0 years.

Burial 167

Child/adolescent aged 8.5–12.5 years. Trace ESA clustering is not clearly suggestive of natality. Sr isotope analysis suggests birth in the Americas/New York.

Burial 168

Male of indeterminate age. Individual has several enthesopathies in the upper limbs.

Burial 169

Child aged 5.5–9.5 years. Cribra orbitalia and diploic expansion indicate nutritional deficiency. Trace ESA clustering suggests birth in the Americas/New York.

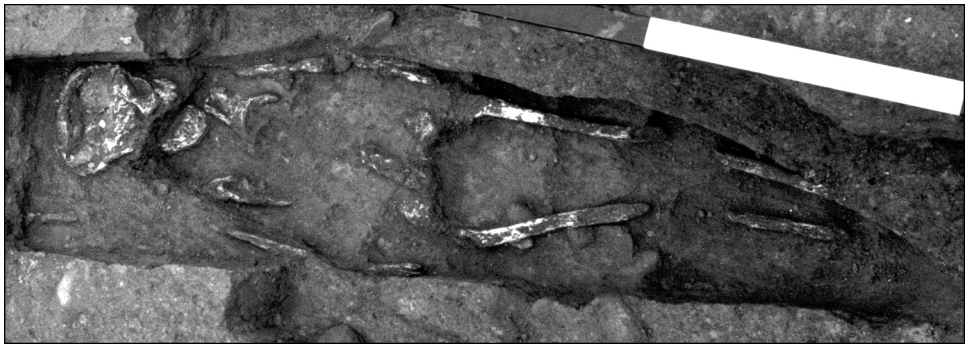

Burial 170

Child aged 7–11.0 years.

Burial 171

Male aged 44–60 years. There is evidence of cranial and lower- and upper-limb periostitis. The individual has enthesopathies or significant hypertrophies at all muscle and ligament attachments examined. Moderate to severe osteoarthritis affects at least one articulation in all axial and appendicular joint regions. Bilateral sacroiliac fusion is present. Healed cribra orbitalia indicative of nutritional stress can be observed. Hypoplasia indicators of childhood stress are also present.

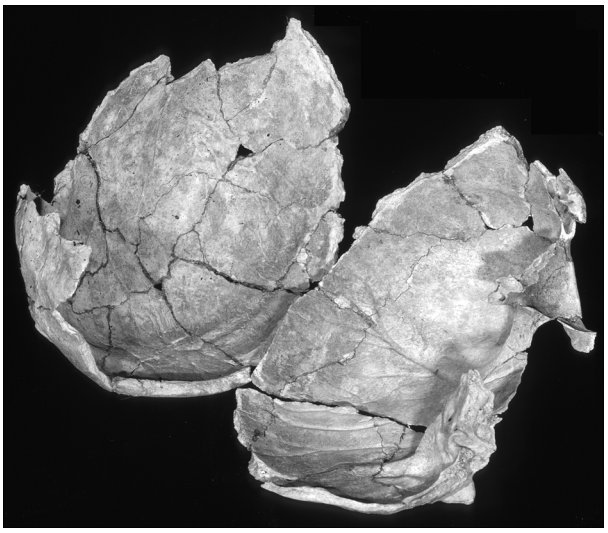

Burial 172

Female aged 25–34.9 years. Evidence of lower-limb periostitis and possible treponemal disease is present. The skeleton has significant muscle-attachment hypertrophy throughout, with enthesopathies on the ulnae and tibiae. Mild osteoarthritis affects the hand and ribs, and there are moderate changes in the knee joint. Cervical osteophytes are present.

Burial 173

Infant aged .25–.75 years.



Burial 174

Male aged 17–18 years. Individual has a moderate number of muscle attachments with hypertrophy or enthesopathies. Mild osteoarthritis affects the ankle, and moderate changes are present in the synovial joints of the lumbar vertebrae. Healed porotic hyperostosis and cribra orbitalia indicative of nutritional stress can be observed.

Burial 175

Male aged 24–28 years. There is evidence of lower-limb periostitis. Individual has multiple enthesopathies of the humeri and ulnae with significant muscle-attachment hypertrophies throughout the skeleton. Mild osteoarthritis affects the knee and ankle. Significant lipping is present at the acetabula. Lumbar osteophytosis and Schmorl's nodes are found in the vertebrae. Healed porotic hyperostosis and cribra orbitalia indicative of nutritional stress can be observed.

Burial 176

Male aged 20–24 years. Lower- and upper-limb periostitis is present. The skeleton has significant hypertrophy of three attachments in the upper limb. Mild lipping affects the elbow, ribs, and synovial joints of the cervical vertebrae. Active, healing, and healed porotic hyperostosis and diploic expansion indicative of nutritional stress can be observed.

Burial 177

Adult aged 30–60 years. Sex indeterminate.

Burial 178

Adult male of indeterminate age. Mild lipping affects the lumbar synovial joints.

Burial 179

Male aged 25–30 years. There is evidence of cranial and lower-limb periostitis and possible treponemal disease. Individual has significant hypertrophy at several muscle insertions and milder hypertrophy at remaining attachments. Enthesopathies and myositis ossificans are present. There is evidence of osteophytosis of the vertebrae, with severe osteoarthritis and Schmorl's nodes observable. Active, healing, and healed porotic hyperostosis and healed cribra orbitalia indicative of nutritional stress can be observed. Hypoplasia indicators of childhood stress are present.

Burial 180

Child/adolescent aged 11–13 years. Individual has lower-limb periostitis. Mild porosity on articular surface of the humeral and femoral heads is present. There is evidence of femoral/tibial bowing associated with rickets. Trace ESA clustering is not clearly suggestive of natality. Sr isotope analysis suggests birth in the Americas/New York.

Burial 181

Male aged 20–23 years. Lower-limb periostitis and possible treponemal disease. Enthesopathies are present on the left fibula and right humerus. Moderate to severe osteoarthritis affects the sacroiliac joint, shoulder, and ankle. Thoracic Schmorl's nodes are present.

Burial 182

Child/adolescent aged 7.5–12.5 years.

Burial 183

Infant aged .63–1.13 years.



Burial 184

Infant aged 1.0–1.5 years.



Burial 185

Male aged 21–23 years. There is evidence of lower- and upper-limb periostitis. Multiple enthesopathies and significant muscle-attachment hypertrophies concentrated in the upper limb are present. Mild osteoarthritis affects the hip, knee, and elbow, with moderate changes in the hand . Hypoplasias indicative of childhood stress are present.

Burial 186

Infant aged 0–.17 years. Healed cribra orbitalia indicative of nutritional stress can be observed.

Burial 187

Infant aged 1.5–4.0 years. Hypoplasia and hypocalcification indicators of childhood stress are present.

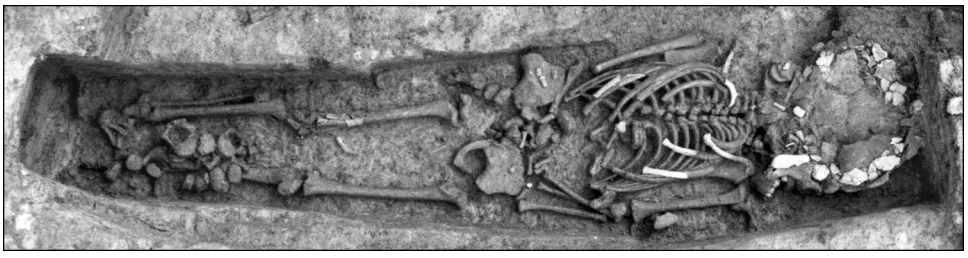

Burial 188

Adult 26–32 years. Lower-limb periostitis is present.

Burial 189

Adult of indeterminate age and sex. Osteomyelitis can be observed.

Burial 190

Infant age .38–.88 years. Cribra orbitalia indicative of nutritional stress can be observed.

Burial 191

Male aged 25–30 years. Individual has lower-limb periostitis. Multiple enthesopathies and significant muscle-attachment hypertrophies are present throughout the skeleton. Mild osteoarthritis affects the wrist and hand with moderate changes of the ankle and foot joints. Lumbar osteophytes are present. Healed porotic hyperostosis and cribra orbitalia indicative of nutritional stress can also be observed.

Burial 192

Female aged 40–60 years. A number of enthesopathies and significant muscle-attachment hypertrophies are scattered throughout the skeleton. Severe osteoarthritis with eburnation is present in the elbow, wrist, ankle, and foot . Healed porotic hyperostosis and diploic expansion indicative of nutritional stress can be observed.

Burial 193

Male aged 30–48 years. There is evidence of lower-limb periostitis. Several enthesopathies of the upper limb and significant muscle-attachment hypertrophies throughout the skeleton are present. Moderate osteoarthritis affects the hip, elbow, and shoulder. Femoral/tibial bowing associated with rickets was observed.



Burial 194

Male aged 30–40 years. Individual has lower-limb periostitis. Enthesopathies of the attachments surrounding the intertubercular groove of the humeri and other attachments exhibit significant muscle-attachment hypertrophy. Lumbar osteophytes are present, and moderate osteoarthritis affects the elbow, knee, ankle, and foot. Diploic expansion indicative of nutritional stress can be observed.

Burial 195

Female aged 30–40 years. Evidence of lower-limb periostitis is present. Numerous enthesopathies and muscle-attachment hypertrophies are concentrated in the upper limbs. Mild to moderate osteoarthritis affects most joints in the axial and appendicular skeleton, with carpal-joint fusion in the wrist. Cervical and thoracic osteophytes are present. Healed porotic hyperostosis and cribra orbitalia indicate nutritional deficiency.

Burial 196

Adult aged 20–24 years. Healed porotic hyperostosis indicative of nutritional stress can be observed.

Burial 197

Female aged 45–55 years. Individual has lower-limb periostitis. Numerous enthesopathies and muscle-attachment hypertrophies occur throughout the skeleton. Mild to severe osteoarthritis affects most axial and appendicular joints. Cervical and thoracic osteophytes are present. Healed porotic hyperostosis indicative of nutritional stress can be observed.

Burial 198

Subadult of indeterminate age.

Burial 199.1

Female aged 30–40 years. Lower-limb periostitis is present. Moderate numbers of enthesopathies and significant muscle-attachment hypertrophies are present throughout the skeleton. Mild to severe osteoarthritis affects most axial and appendicular joints. Cervical and thoracic osteophytes and myositis ossificans of the left femur are present. Healed porotic hyperostosis indicative of nutritional stress can be observed.

Burial 199.2

Adult male of indeterminate age. (No photograph).

Burial 199.3

Infant aged 0–4.1 years. (No photograph).

Burial 200

Male of indeterminate age. The individual has well-developed deltoid tuberosities on the humeri. Moderate osteoarthritis affects the elbow joint with lumbar and sacral osteophytes present. Hypoplasias indicative of childhood stress are present.

Burial 201

Infant aged 1.50–3.5 years. Periostitis of the lower and upper limbs is present. Hypoplasia and hypocalcification indicators of childhood stress are present.

Burial 202

Female aged 12–18 years. Periostitis of the lower limbs is observable. Femoral/tibial bowing associated with rickets is present.

Burial 203

Adult aged 12–18 years.

Burial 204

Female of indeterminate age. Individual has a few enthesopathies and significant muscle-attachment hypertrophies on the humeri and clavicles. Mild to moderate osteoarthritis affects the ribs and shoulder joints with cervical osteophytes also present.

Burial 205

Female aged 18–20 years. Individual has several enthesopathies and significant muscle-insertion hypertrophies, primarily in the upper limb . Mild osteoarthritis affects appendicular joints. Hypoplastic indicators of childhood stress are present.

Burial 206

Subadult of indeterminate age.

Burial 207

Female aged 25–35 years. Periostitis of the lower limbs is present, with enthesopathies of the linea aspera and significant muscle-attachment hypertrophies on the ulnae and tibiae. Mild osteoarthritis is present which affects the knee, ankle and foot. Diploic expansion indicative of nutritional stress can be observed.

Burial 208

Infant aged .5–1.0 years.

Burial 209

Male aged 40–50 years. Individual has periostitis of the crania and lower and upper limbs, lower-limb osteomyelitis, saber shins, and possible treponemal disease. Numerous enthesopathies and significant muscle-insertion hypertrophies are present throughout the skeleton. Moderate to severe osteoarthritis affects most axial and appendicular joints. Also present is osteophytosis of the vertebrae, with observable Schmorl's nodes. Active, healing, and healed porotic hyperostosis with diploic expansion indicative of nutritional stress can also be observed.

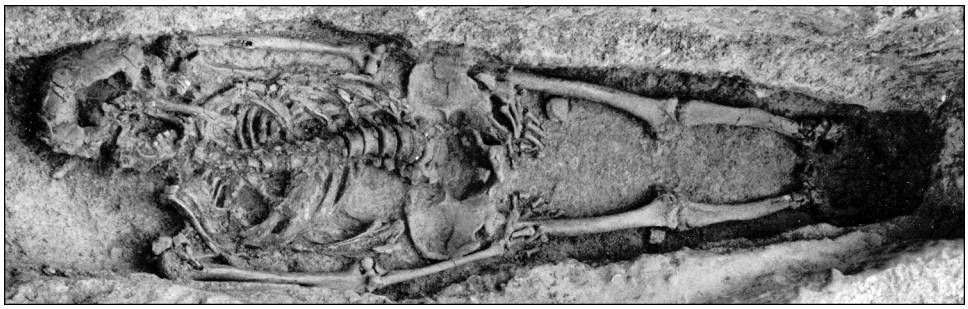

Burial 210

Male aged 35–45 years. Periostitis of the crania, lower and upper limbs with enthesopathies, and many muscle attachments with significant hypertrophy can be seen throughout the skeleton. Moderate to severe osteoarthritis affects most axial and appendicular joints. Osteophytes are present, and there is endplate collapse in the lumbar vertebrae. Healed porotic hyperostosis and cribra orbitalia indicative of nutritional stress can also be observed. Hypoplasia indicators of childhood stress are present.

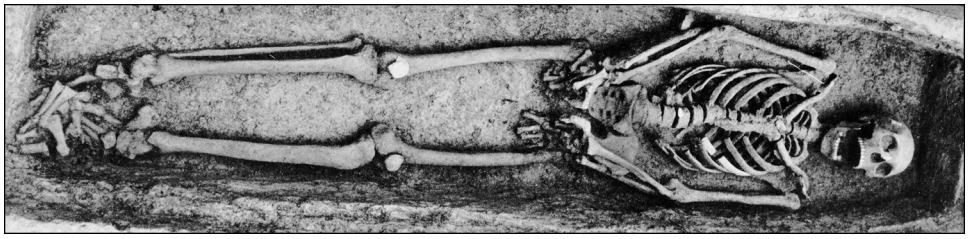

Burial 211

Adult of indeterminate age and sex.

Burial 212

Child aged 4.5–5.5 years. Individual has lower-limb periostitis.

Burial 213

Female aged 45–55 years. Individual has a moderate number of enthesopathies and muscle attachments with significant hypertrophy throughout the skeleton. Mild to moderate lipping affects the lumbar synovial joints and sacroiliac articulation. Diploic expansion indicative of nutritional stress can be observed.



Burial 214

Male aged 45–55 years. There is evidence of lower- and upper-limb periostitis. Throughout the skeleton are numerous enthesopathies and significant muscle-attachment hypertrophies. Moderate to severe osteoarthritis affects most axial and appendicular joints. Cervical, thoracic, and lumbar osteophytosis is present. There is evidence of femoral/tibial bowing associated with rickets. Healed porotic hyperostosis and cribra orbitalia with diploic expansion indicative of nutritional stress can be observed. Hypoplastic indicators of childhood stress are also present. Sr isotope analysis suggests birth in Africa.

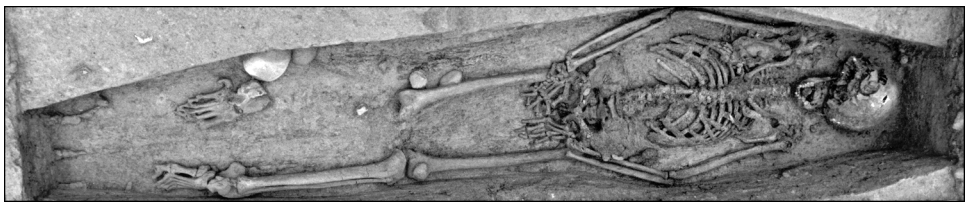

Burial 215

Infant aged 0–.16 years.

Burial 216

Infant aged 0–.16 years.

Burial 217

Male aged 17–19 years. Individual has periostitis of the crania and lower limbs, with numerous enthesopathies and significant muscle-attachment hypertrophies throughout the skeleton. Mild to severe osteoarthritis affects most axial and appendicular joints. There is evidence of femoral/tibial bowing associated with rickets. Healed porotic hyperostosis and active and healing cribra orbitalia with diploic expansion indicative of nutritional stress can be observed. Hypoplastic indicators of childhood stress are present.

Burial 218

Infant aged .50–3.5 years.



Burial 219

Child aged 4–5 years. There is evidence of lower- and upper-limb periostitis present. Individual has lytic syndesmopathy of the rhomboid ligament attachment. There is evidence of femoral/tibial bowing associated with rickets. Trace ESA clustering suggests birth in the Americas/New York. Sr isotope analysis also suggests birth in the Americas/New York.

Burial 220

Subadult of indeterminate age.

Burial 221

Male aged 30–60 years. There is evidence of lower-limb periostitis and possible treponemal disease. A moderate number of significant muscle-insertion hypertrophies are observable throughout the skeleton. Mild osteoarthritis affects the knee and ankle with moderate changes in the joints of the hand. Healed porotic hyperostosis indicative of nutritional stress can be observed.

Burial 222

Male of indeterminate age. Evidence of lower-limb periostitis and possible treponemal disease is present. Enthesopathies and significant muscle-attachment hypertrophies occur throughout the skeleton. Mild osteoarthritis affects the elbow with moderate changes in the wrist and ankle. There is observable femoral/tibial bowing associated with rickets.

Burial 223

Female aged 25–35 years. There is evidence of lower-limb periostitis, possible treponemal disease, and several enthesopathies. A moderate number of significant hypertrophies is observable. Moderate to severe osteoarthritis affects most axial and appendicular joints. Osteophytes and thoracic Schmorl's nodes are present.

Burial 224

Infant aged .5–1.33 years. Hypoplasias and hypocalcifications indicative of childhood stress are present.

Burial 225

Infant aged .50–1.25 years. Periostitis of the crania and lower and upper limbs is present. Healed cribra orbitalia indicative of nutritional stress can also be observed.

Burial 226

Infant aged 0–.17 years



Burial 227

Indeterminate age and sex. Lower-limb periostitis is observable.

Burial 228

Male adult of indeterminate age. Individual has lower-limb periostitis and possible treponemal disease. Enthesopathies and several muscle attachments with significant hypertrophies are present. Mild to moderate osteoarthritis affects the appendicular joints that are present. There is evidence of femoral/tibial bowing associated with rickets.

Burial 229

Child aged 6.75–11.25 years. Hypoplastic indicators of childhood stress are present.

Burial 230

Female aged 55–65 years. There is evidence of lower-limb periostitis with numerous enthesopathies and muscle-insertion hypertrophies. Moderate to severe osteoarthritis affects most axial and appendicular joints. Cervical and lumbar osteophytosis is present. Active and healing cribra orbitalia, healed porotic hyperostosis, and diploic expansion indicative of nutritional stress can be observed.



Burial 231

Subadult of indeterminate age. (No photograph.)

Burial 232

Subadult, age unknown.

Burial 233

Age and sex indeterminate.

Burial 234

Infant aged 0–4.1 years.



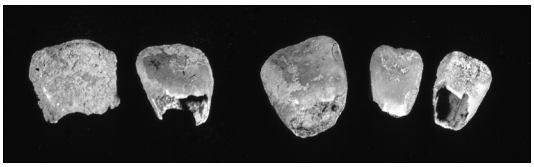

Burial 235

Female aged 28–42 years. Individual has several enthesopathies and muscle attachments with significant hypertrophies. Moderate to severe osteoarthritis primarily affects the lower-limb joints.



Burial 236

Child aged 4–5 years. Diploic expansion indicative of nutritional stress can be observed. Trace ESA clustering is not clearly suggestive of natality. Sr isotope analysis suggests birth in the Americas/New York

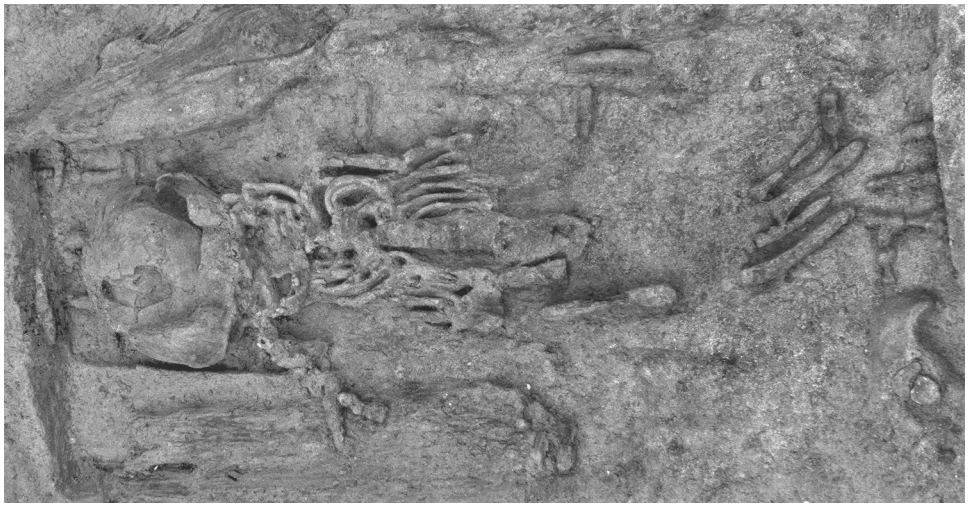

Burial 237

Age and sex are indeterminate.

Burial 238

Male aged 40–50 years. There is evidence of lower-limb periostitis and possible treponemal disease. Numerous enthesopathies and significant muscle-attachment hypertrophies are present. Moderate to severe osteoarthritis affects most axial and appendicular joints. Osteophytosis is present throughout the vertebral column. Healed porotic hyperostosis and diploic expansion indicative of nutritional stress can be observed. Hypoplastic indicators of childhood stress are also present.

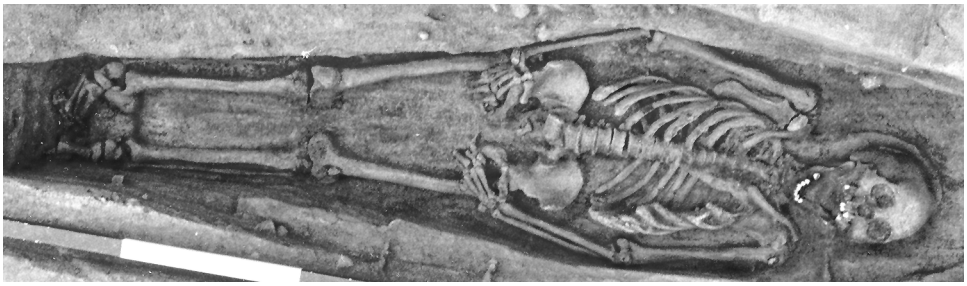

Burial 239

Infant aged 1.5–3.5 years. Diploic expansion indicative of nutritional stress can be observed. Hypocalcification and hypoplasia indicators of childhood stress are present.

Burial 240

Infant aged .88–2.66 years.

Burial 241

Female aged 55–65 years. Individual has lower- and upper-limb periostitis and possible treponemal disease. Numerous enthesopathies and muscle attachments with significant hypertrophies are present. Moderate osteoarthritis affects most appendicular joints. Osteophytosis is present throughout the vertebral column. There is evidence of femoral/tibial bowing associated with rickets.

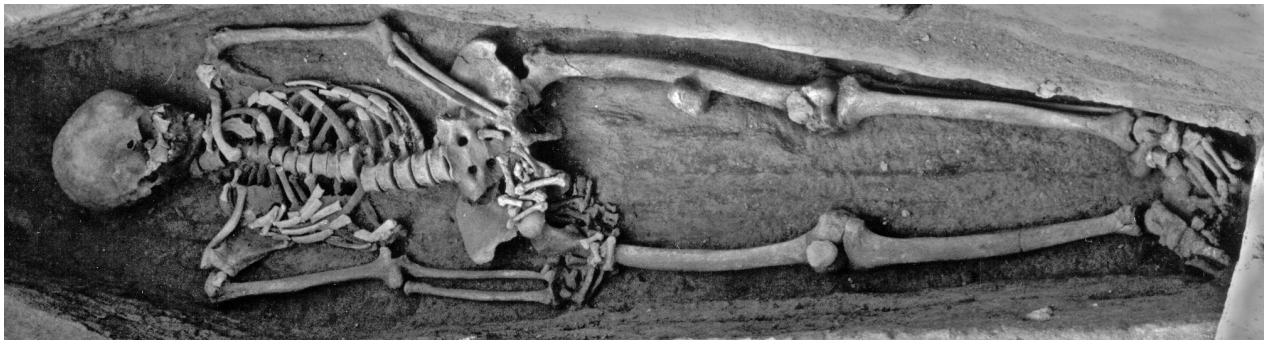

Burial 242

Female aged 40–50 years.

Burial 243

Male aged 40–50 years.

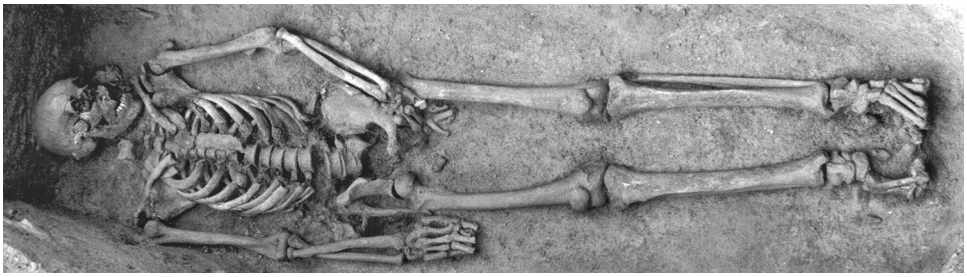

Burial 244

Child aged 5–9 years.

Burial 245

Child aged 2.5–4.5 years. Hypoplasia and hypocalcification indicators of childhood stress are present.

Burial 246

Infant aged .50–2.9 years.

Burial 247

Male aged 35–45 years. Individual has lower- and upper-limb periostitis and possible treponemal disease. Numerous enthesopathies and significant muscle-attachment hypertrophies are present. Moderate osteoarthritis affects most appendicular joints. Diploic expansion indicative of nutritional stress can be observed.

Burial 248

Child/adolescent aged 14–15 years.

Burial 249

Infant aged .67–1.33 years. Hypoplasia indicators of childhood stress are present.

Burial 250

Adult of indeterminate age.

Burial 251

Subadult aged 12–24 years.

Burial 252

Infant aged 1–2 years. Individual has lower- and upper-limb and cranial periostitis. Healed porotic hyperostosis indicative of nutritional stress can also be observed. Hypocalcification indicators of childhood stress are present.

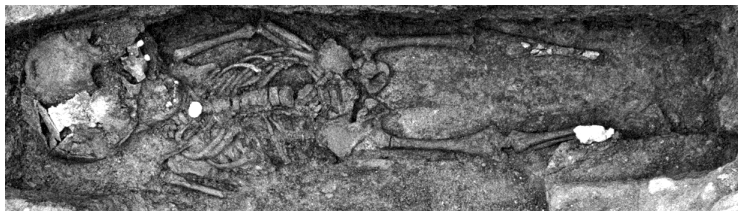

Burial 253

Child/adolescent aged 13–15 years. There is evidence of cranial and lower- and upper-limb periostitis. Individual has syndesmophytes and enthesophytes of the clavicles. Myositis ossificans on the thoracic vertebrae is observable. Diploic expansion indicative of nutritional stress is also present.

Burial 254

Child aged 3.5–5.5 years. Diploic expansion indicative of nutritional stress can be observed. There is also evidence of femoral/tibial bowing associated with rickets.

Burial 255

Infant aged 0–.17 years.

Burial 256

Male aged 40–60 years.

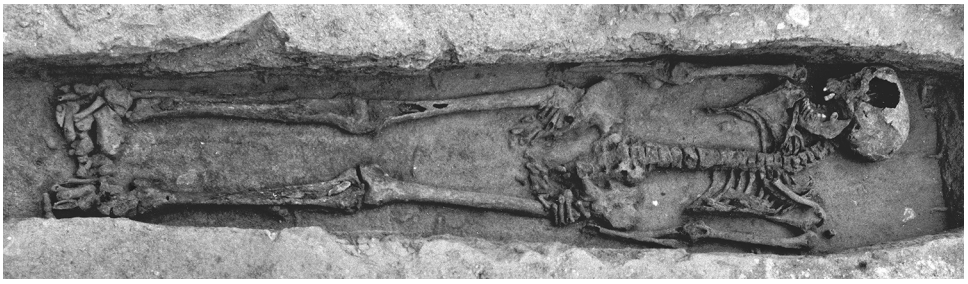

Burial 257

Male aged 30–40 years.

Burial 258

Infant aged 0–.50 years.

Burial 259

Female aged 17–19 years. There is evidence of lower-limb periostitis and possible treponemal disease. Several enthesopathies and significant muscle-insertion hypertrophies are present, primarily on the upper limbs. Moderate osteoarthritis affects the elbow and knee, and mild changes are present in the hand and ankle joints.

Burial 260

Age and sex indeterminate. There is periostitis of the lower limbs, saber shins, and possible treponemal disease.

Burial 261

Empty shaft. (No photograph.)

Burial 262

Male aged 15–17 years. Hypoplasia indicators of childhood stress are present. Sr isotope analysis suggests birth in the Americas/New York.

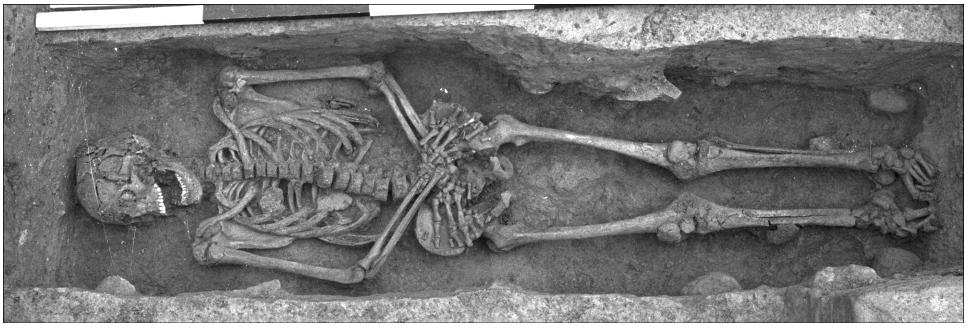

Burial 263

Subadult of indeterminate age.

Burial 264

Adult of indeterminate age and sex.

Burial 265

Infant aged .50–1.0 years.

Burial 266

Female aged 25–35 years. Trace ESA clustering, Sr isotope analysis, and low Pb concentration suggest birth in Africa.

Burial 267

Adult of indeterminate age and sex.

Burial 268

Infant aged 0–.50 years. Evidence of periostitis of the lower and upper limbs.

Burial 269

Adult of indeterminate age and sex.

Burial 270

Male of indeterminate age. There is evidence of lower-limb periostitis, saber shins, and possible treponemal disease. Individual has enthesopathies on the tibiae and well-developed linea aspera on the femora. Moderate osteoarthritis affects the ankle and foot with mild changes in the knee. There is evidence of femoral/tibial bowing associated with rickets. Trace ESA clustering suggests birth in Africa; however, low Sr isotope values suggest birth possibly in the Caribbean.

Burial 271

Male aged 45–55 years. There is evidence of periostitis of the lower and upper limbs, saber shins, and possible treponemal disease. Numerous enthesopathies and significant muscle-attachment hypertrophies are observable. Moderate osteoarthritis affects all appendicular joints. Diploic expansion indicative of nutritional stress can also be observed.

Burial 272

Infant aged .25–.75 years.

Burial 273

Age and sex indeterminate. There is evidence of periostitis of the lower limbs and possible treponemal disease.

Burial 274

Female of indeterminate age.

Burial 275

Female of indeterminate age. Femora exhibit significant muscle-attachment hypertrophies.

Burial 276

Female aged 20–24 years. Hypoplastic indicators of childhood stress are present.

Burial 277

Subadult of indeterminate age.

Burial 278

Male aged 45–55 years. There is evidence of periostitis of the lower limbs and possible treponemal disease. Numerous enthesopathies and significant muscle-attachment hypertrophies are present. Mild to moderate osteoarthritis affects most axial and appendicular joints. Osteophytosis, cervical Schmorl's nodes, and cervical spondylolysis are present.

Burial 279

Adult of indeterminate age and sex.

Burial 280

Adult female of indeterminate age.

Burial 281

Male of indeterminate age. Trace ESA clustering suggests birth in Africa; however, Sr isotope analysis suggests birth probably in the Americas/New York.

Burial 282

Male aged 32.5–42.5 years. Cranial and lower-limb periostitis with several significant enthesopathies and muscle-attachment hypertrophies are present. Mild to moderate osteoarthritis affects the hand, hip, knee, ankle , and cervical vertebrae. Healed cribra orbitalia indicative of nutritional stress can be observed.

Burial 283

Infant aged .33–.67 years. Hypoplasia and hypocalcification indicators of childhood stress are present.

Burial 284

Male aged 21–28 years. There is evidence of lower-limb periostitis with significant enthesopathies and muscle-attachment hypertrophies. Mild to moderate osteoarthritis affects most appendicular joints.

Burial 285

Female aged 20–30 years. Hypoplasia indicators of childhood stress are present.

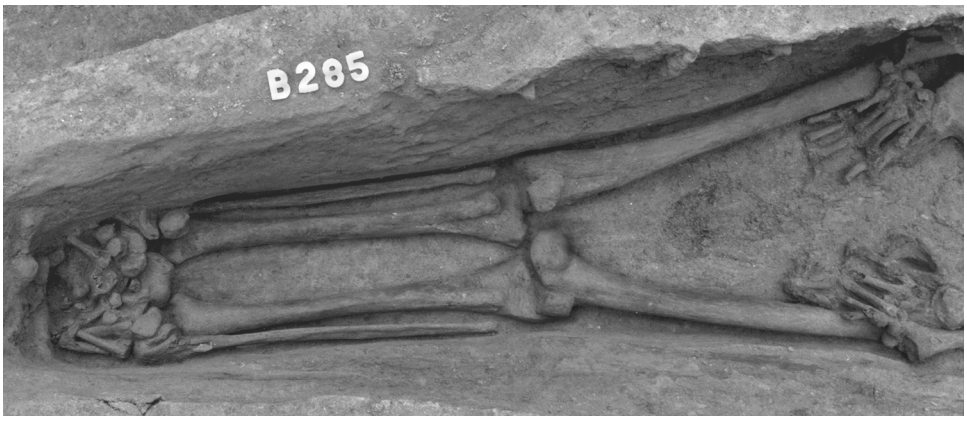

Burial 286

Child aged 4.5–8.5 years. There is evidence of lower-limb periostitis with enthesopathies at gluteal insertions of the femora. Lipping is present at the vertebral articulations. Healed porotic hyperostosis indicative of nutritional stress can be observed.

Burial 287

Male aged 18–20 years. There is evidence of lower-limb periostitis and possible treponemal disease. Several enthesopathies and significant muscle-attachment hypertrophies are present. Moderate osteoarthritis affects the elbow and lumbar vertebrae.

Burial 288

Adult of indeterminate age. There is evidence of periostitis of the lower limbs.

Burial 289

Child aged 5–9 years. Diploic expansion indicates nutritional stress.

Burial 290

Male aged 45–55 years. Individual has several enthesopathies and significant muscle attachment with hypertrophy. Mild to moderate osteoarthritis affects the upper-limb joints. Diploic expansion indicative of nutritional stress can be observed.

Burial 291

Infant aged 3–5 years.

Burial 292

Adult of indeterminate age and sex.

Burial 293

Adult male of indeterminate age. Individual has several significant muscle-attachment hypertrophies.



Burial 294

Subadult .5–1 year.

Burial 295

Female aged 30–50 years. Individual has well-developed linea aspera and gluteal attachments on the femora.

Burial 296

Infant aged .50–2.9 years.

Burial 297

Male aged 30–40 years. There is evidence of lower-limb periostitis with several enthesopathies and significant muscle-insertion hypertrophies. Mild to severe osteoarthritis affects many appendicular joints. Fusion of foot phalanges is present.

Burial 298

Infant aged .67–1.33 years.

Burial 299

Male aged 40–50 years. Individual has lower-limb periostitis and possible treponemal disease. There is evidence of enthesopathies and significant muscle-attachment hypertrophies. Mild to severe osteoarthritis affects many axial and appendicular joints; cervical osteophytosis is also present. Femoral/tibial bowing associated with rickets is present. Healed porotic hyperostosis, cribra orbitalia, and diploic expansion indicative of nutritional stress can be observed.

Burial 300

Subadult of indeterminate age.

Burial 301

Adult of indeterminate age and sex.

Burial 301.2

Subadult of indeterminate age.

Burial 302

Adult female of indeterminate age. Individual has significant muscle-attachment hypertrophy of the tibiae.

Burial 303

Infant aged .50–1 year.

Burial 304

Child aged 3–4.9 years. Healed cribra orbitalia and diploic expansion indicative of nutritional stress is observable. Trace ESA clustering and low Pb concentration suggest birth in the Americas/New York

Burial 305

Infant aged -.33–.33 years. Active cribra orbitalia and diploic expansion indicative of nutritional stress can be observed.

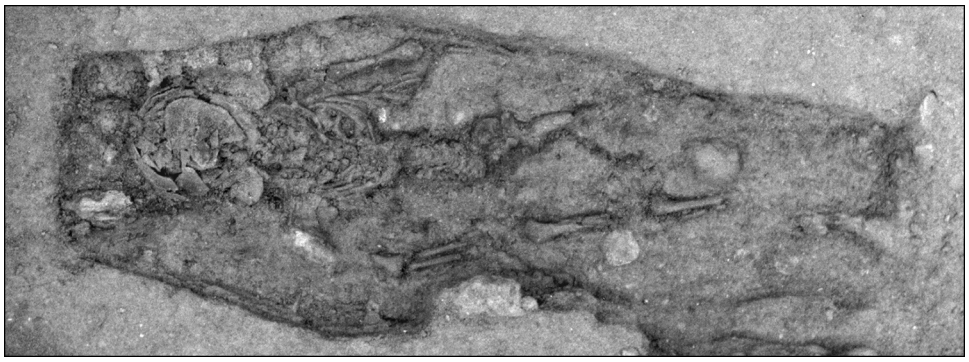

Burial 306

Male aged 28–44 years. Periostitis of the lower limbs and possible treponemal disease are evident. The skeleton has several significant muscle-attachment hypertrophies. Mild osteoarthritis affects several appendicular joints, with moderate changes at the hip joint. Cervical osteophytes are present. Healed porotic hyperostosis indicative of nutritional stress can be observed.

Burial 307

Male aged 45–55 years. A small degree of osteoarthritis affects the elbow.

Burial 308

Subadult of indeterminate age.

Burial 309

Male aged 20–25 years. Individual has a few enthesopathies and muscle attachments with significant hypertrophies. Moderate osteoarthritis affects the elbow, hip, and lumbar vertebrae. There is evidence of femoral/tibial bowing associated with rickets.

Burial 310

Female aged 44–52 years. Individual has numerous enthesopathies with significant muscle-attachment hypertrophies, primarily in the upper limb. Moderate to severe osteoarthritis affects many axial and appendicular joints.

Burial 311

Infant aged .25–.75 years. Healed cribra orbitalia indicative of nutritional stress can also be observed.



Burial 312

Infant aged 0–.30 years.

Burial 313

Male aged 45–55 years. Hypoplasia indicators of childhood stress are present.

Burial 314

Male aged 40–50 years. Periostitis of the lower and upper limbs is present. Individual has numerous enthesopathies and muscle attachments with significant hypertrophies. Mild to moderate osteoarthritis affects the joints of the lower limb, lumbar vertebrae, wrist, and hand . Lumbar Schmorl's nodes are present. Diploic expansion indicative of nutritional stress can be observed.

Burial 315

Female aged 30–40 years. Periostitis of the lower limbs is observable. The skeleton has syndesmophytes in the clavicles and enthesopathies at the brachialis insertions of the ulnae. Mild to moderate osteoarthritis is present in the vertebral column, elbow, hip, and ankle.

Burial 316

Female aged 18–20 years. Individual has a few enthesopathies with significant muscle-attachment hypertrophies. Mild osteoarthritis affects the cervical and thoracic vertebrae, ribs, and hip. Moderate changes are present in the lumbar vertebrae. Cervical osteophytosis and lumbar Schmorl's nodes are present. Healed cribra orbitalia indicative of nutritional stress can also be observed.

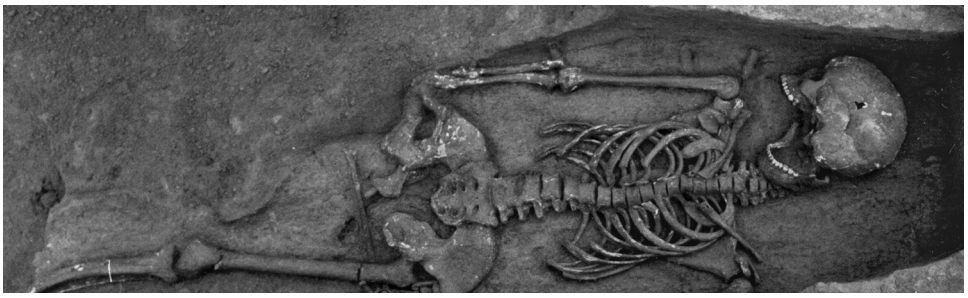

Burial 317

Male aged 19–39 years. Lower-limb periostitis is evident. Individual has well-developed linea aspera and mild osteoarthritis in the hip.

Burial 318

Child/adolescent aged 7.5–14 years. There is evidence of periostitis on the lower limbs.

Burial 319

Adult of indeterminate age. There is evidence of periostitis of the lower limbs with a well-developed linea aspera and gluteal insertions of the femora.

Burial 320

Child aged 2–4 years.

Burial 321

Infant aged 1–2 years. Diploic expansion indicative of nutritional stress can be observed. Hypoplasia and hypocalcification indicators of childhood stress are present.

Burial 322

Female of indeterminate age. Individual has lower-limb periostitis and lumbar osteophytosis. There is also evidence of femoral/tibial bowing associated with rickets.

Burial 323

Male aged 19–30 years. This individual exhibits some periostitis of the lower limbs and cranial evidence of infection on the bone; he also has numerous enthesopathies and muscle attachments with significant hypertrophies. Mild to moderate osteoarthritis affects many axial and appendicular joints. Osteophytosis and thoracic Schmorl's nodes are present. Healed porotic hyperostosis indicative of nutritional stress can be observed. Sr isotope analysis suggests birth in the Americas/New York.

Burial 324

Female aged 25–35 years. Individual has cranial and lower- and upper-limb periostitis and possible treponemal disease. Several enthesopathies and muscle attachments with significant hypertrophies are present. Mild osteoarthritis affects the vertebral column, hand, ankle, and foot. Diploic expansion indicative of nutritional stress can also be observed.

Burial 325

Male aged 25–35 years. There is evidence of periostitis of the lower and upper limbs, saber shins, and possible treponemal disease. Robust development of long bones, with hypertrophy of a few specific muscle attachments, is present. Diploic expansion indicative of nutritional stress can be observed.

Burial 326

Male aged 45–55 years. Sr isotope analysis (of dentin only) is not clearly suggestive of natality.

Burial 327

Male aged 35–45 years. There is evidence of lower-limb periostitis. Several enthesopathies and muscle attachments with significant hypertrophies, primarily in the upper limbs, are observable. Mild to moderate osteoarthritis affects several axial and appendicular joints. Cervical osteophytosis is present. Diploic expansion and healed porotic hyperostosis indicative of nutritional stress can also be observed.

Burial 328

Female aged 40–50 years.

Burial 329

Adult male of indeterminate age. Individual has cranial and lower-limb periostitis and possible treponemal disease. Numerous enthesopathies and muscle attachments with significant hypertrophies can be observed. Mild to moderate osteoarthritis affects several axial and appendicular joints, and cervical osteophytosis is present.

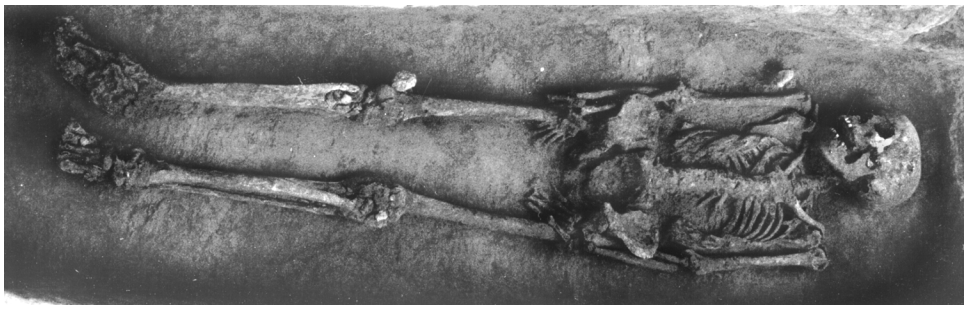

Burial 330

Male aged 28–58 years.

Burial 331

Adult aged 30–35 years.



Burial 332

Male aged 35–40 years. Periostitis of the cranium and lower limbs and possible treponemal disease are evident. Individual has enthesopathies of the humeri and femora. Healed cribra orbitalia and porotic hyperostosis with diploic expansion indicative of nutritional stress can be observed.

Burial 333

Male aged 45–55 years.

Burial 334

Subadult of indeterminate age.



Burial 335

Female aged 25–34.9 years. There is evidence of lower-limb periostitis and possible treponemal disease. Numerous enthesopathies and muscle attachments with significant hypertrophies are present. Mild to moderate osteoarthritis affects several axial and appendicular joints. Sacral osteophytosis and lumbar Schmorl's nodes are present. Healed porotic hyperostosis indicative of nutritional stress can be observed. Hypoplasia indicators of childhood stress are present.

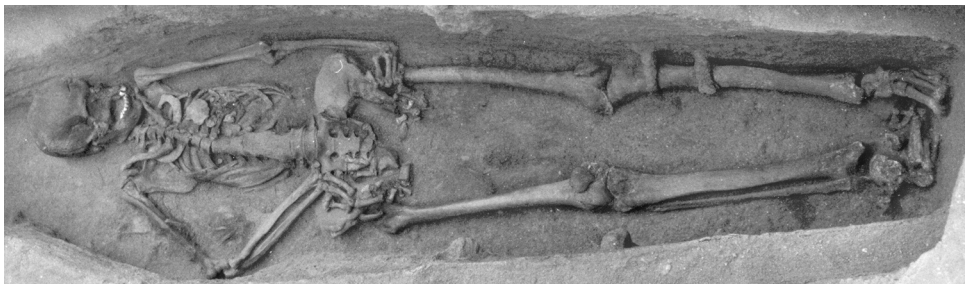

Burial 336

Infant aged .50–1.0 years.



Burial 337

Male aged 40–50 years. Individual has lower-limb periostitis and numerous enthesopathies and muscle attachments with significant hypertrophies. Mild to moderate osteoarthritis affects several axial and appendicular joints with cervical osteophytosis. Healed porotic hyperostosis indicative of nutritional stress can be observed. Hypoplastic indicators of childhood stress are present.

Burial 338

Female aged 33–65 years. Individual has lower-limb periostitis, and enthesopathies are present on the femora and patellae. Mild osteoarthritis affects the hip with moderate changes in the knee and elbow.

Burial 339

Subadult of indeterminate age.

Burial 340

Female aged 39.3–64.4 years. Evidence of lower-limb periostitis is observable. Individual has enthesopathies of the gluteal attachments on the femora and significant hypertrophy of the lateral scapulae and flexor attachments on the ulnae. Moderate osteoarthritis affects the hip with mild changes in the shoulder; osteophytosis affects the cervical and lumbar vertebrae. Diploic expansion indicative of nutritional stress can also be observed.

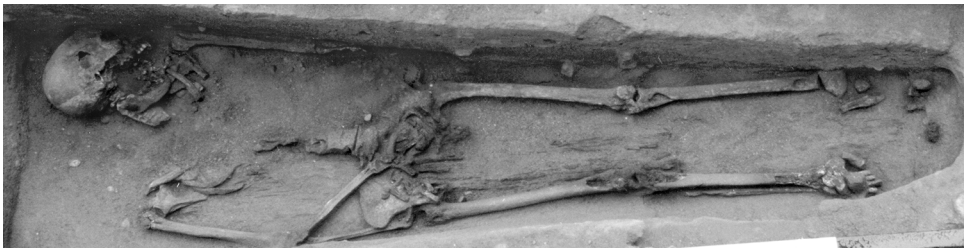

Burial 341

Male of indeterminate age. Periostitis of the lower and upper limbs is present. Individual has several enthesopathies of the humeri, ulnae, and femora. Mild osteoarthritis affects the knee. Bilateral sacroiliac fusion and vertebral osteophytes are present. Diploic expansion indicative of nutritional stress can be observed.

Burial 342

Female aged 25–34.9 years. Periostitis of the lower limbs and several enthesopathies and muscle attachments with significant hypertrophies are present. Mild to moderate osteoarthritis affects several axial and appendicular joints; also present are lumbar osteophytosis and Schmorl's nodes. Healed porotic hyperostosis indicative of nutritional stress can be observed.

Burial 343

Male aged 19–23 years. There is evidence of cranial and lower- and upper-limb periostitis. Individual has enthesopathies of the occipital and syndesmophytes on the clavicle. Mild to moderate osteoarthritis affects the shoulder, hand, ankle, and cervical vertebrae. Healed cribra orbitalia indicative of nutritional stress can be observed. Hypoplastic indicators of childhood stress are present.

Burial 344

Male aged 25–34.9 years. Individual has many enthesopathies and muscle attachments with significant hypertrophies. Healed cribra orbitalia and porotic hyperostosis with diploic expansion indicative of nutritional stress can be observed.



Burial 345

Adult of indeterminate age and sex.

Burial 346

Female aged 50–70 years. There is evidence of periostitis of the lower and upper limbs. Several enthesopathies and muscle attachments with significant hypertrophies are present. Moderate to severe osteoarthritis affects the lower limb, and lumbar joints and cervical osteophytosis are present. Diploic expansion indicative of nutritional stress can be observed.

Burial 347

Infant aged .50–1.0 years. Diploic expansion indicative of nutritional stress can be observed.



Burial 348

Infant aged 1.0–2.0 years.

Burial 349

Infant aged 0–4.1 years.

Burial 350

Age and sex indeterminate.

Burial 351

Male aged 50–60 years. Individual has numerous enthesopathies and muscle attachments with significant hypertrophies. Mild to severe osteoarthritis affects nearly all of the axial and appendicular joints. Lumbar osteophytosis and Schmorl's nodes are present. Healed porotic hyperostosis indicative of nutritional stress can be observed.



Burial 352

Male of indeterminate age. There is evidence of lower-limb periostitis, saber shins, and possible treponemal disease. The skeleton has several enthesopathies and muscle attachments with significant hypertrophies. Mild to severe osteoarthritis affects many appendicular joints. Diploic expansion indicative of nutritional stress can be observed.

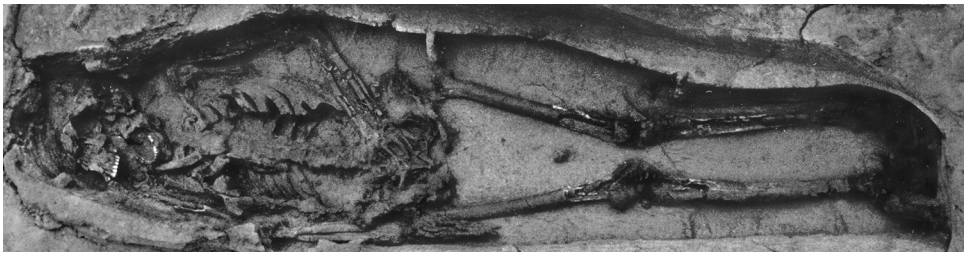

Burial 353

Male aged 24–34 years. Individual has lower- and upper-limb periostitis. The skeleton has numerous enthesopathies and muscle attachments with significant hypertrophies. Mild osteoarthritis affects the shoulder, knee, elbow, and hip and osteophytosis is present throughout the vertebral column. Diploic expansion and healed porotic hyperostosis indicative of nutritional stress can also be observed. Hypoplasia indicators of childhood stress are present.

Burial 354

Male aged 35–45 years. Periostitis of the lower limbs is evident. The skeleton has numerous enthesopathies and muscle attachments with significant hypertrophies. Mild osteoarthritis affects several axial and appendicular joints. Lumbar osteophytosis and Schmorl's nodes are present. Healed porotic hyperostosis indicative of nutritional stress can be observed.

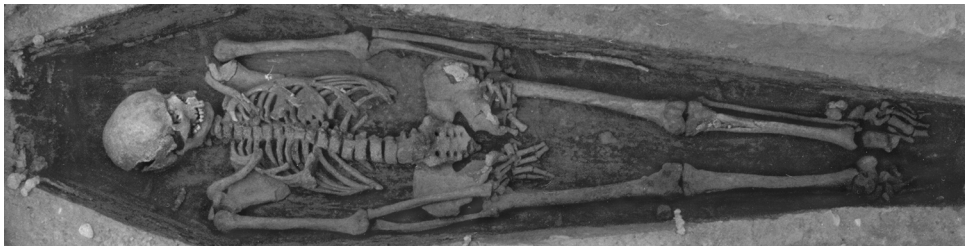

Burial 355

Adult of indeterminate age and sex.

Burial 356

Subadult of indeterminate age. Infant interred with Burial 335 (on right arm).

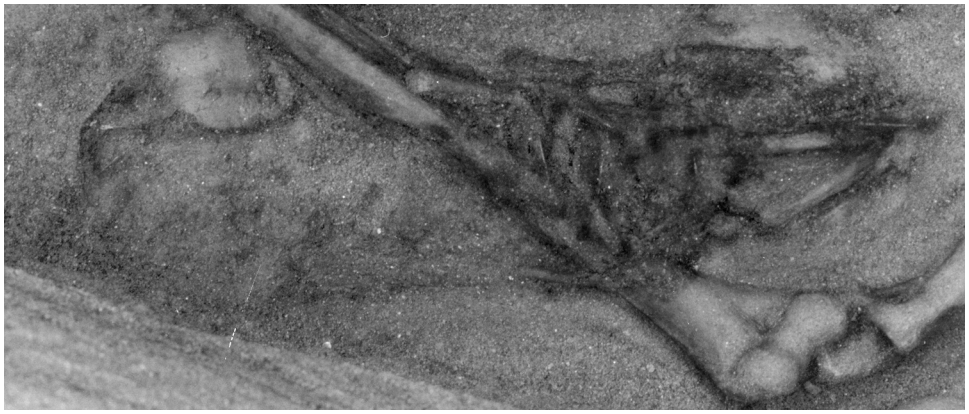

Burial 357

Male aged 45–65 years. Individual has lower-limb periostitis. Enthesopathy is present on the tibiae. Moderate osteoarthritis affects the knee, ankle and wrist.



Burial 358

Adult of indeterminate age and sex.

Burial 359

Subadult of indeterminate age.

Burial 360

Subadult age unknown.

Burial 361

Male aged 33–57 years. Periostitis of the lower limbs and enthesopathies are present on the tibiae and femora. Healed porotic hyperostosis and diploic expansion indicative of nutritional stress can be observed.



Burial 362

Adult of indeterminate age. Diploic expansion indicative of nutritional stress is present.



Burial 363

Infant aged 1–2 years. Meningitis with cranial and lower- and upper-limb periostitis are observable. Hypoplasia and hypocalcification indicators of childhood stress are present.

Burial 364

Male aged 25–35 years. Periostitis of the lower limbs is evident. Individual has several enthesopathies and muscle attachments with significant hypertrophies. Mild osteoarthritis affects the elbow with moderate changes in the ankle.



Burial 365

Adult female of indeterminate age. The individual has lower-limb periostitis and mild osteoarthritis of the knee. Femoral/tibial bowing associated with rickets is present.

Burial 366

Adult of indeterminate age and sex. Periostitis of the lower limbs and possible treponemal disease are observable.



Burial 367

Female aged 25–35 years. Trace ESA clustering, Sr isotope analysis, and low Pb concentration suggest birth in Africa.

Burial 368

Child/adolescent aged 10.5–13.5 years. Healed cribra orbitalia indicative of nutritional stress can be observed.

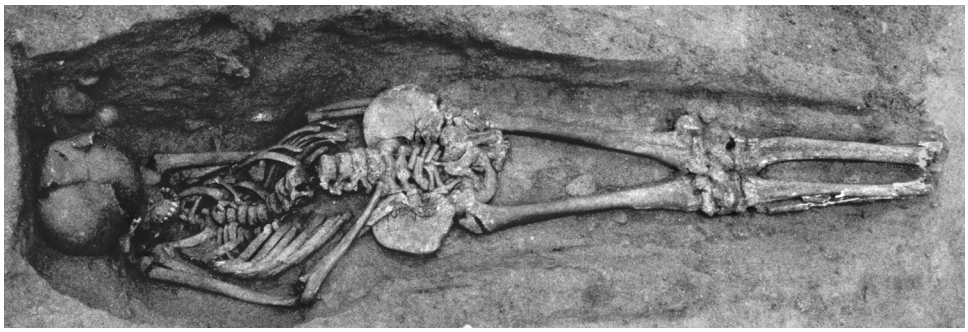

Burial 369

Male aged age 40–50 years. Individual has lower-limb periostitis, saber shins, and possible treponemal disease. Numerous enthesopathies and muscle insertions with significant hypertrophies are present. Mild to severe osteoarthritis affects most axial and appendicular joints. Several carpal bones in both wrists are fused. Osteophytosis and cervical Schmorl's nodes are present. There is evidence of femoral/tibial bowing associated with rickets. Hypoplastic indicators of childhood stress are present.



Burial 370

Child aged 2–4 years. Hypoplastic indicators of childhood stress are present.

Burial 371

Female aged 25–35 years.

Burial 372

Female aged 25–35 years.

Burial 373

Female aged 45–60 years. Individual has several enthesopathies of the ulnae and femora. Moderate osteoarthritis affects the knees with mild changes in the hip.

Burial 374

Infant aged 0–.25 years.

Burial 375

Female aged 16–18 years. Periostitis of the lower limbs is evident. Enthesopathies of the gluteal attachments on the femora and muscle attachments with significant hypertrophies are present. Mild to severe osteoarthritis is present throughout the skeleton.

Burial 376

Male aged 45–65 years. Individual has lower-limb periostitis and numerous enthesopathies and muscle attachments with significant hypertrophies. Mild to severe osteoarthritis affects many axial and appendicular joints. Healed cribra orbitalia and porotic hyperostosis indicative of nutritional stress can be observed.

Burial 377

Female aged 32.6–57.8 years. Individual has numerous enthesopathies at muscle attachments on the preserved remains.

Burial 378

Empty shaft. (No photograph.)

Burial 379

Male aged 30–40 years. Evidence of lower-limb periostitis, saber shins, and possible treponemal disease are present. The skeleton has numerous enthesopathies and muscle attachments with significant hypertrophies. Osteoarthritis affects nearly all axial and appendicular joints. There is fusion of phalanges in both hands. Osteophytosis is present throughout the vertebral column. Healed cribra orbitalia indicative of nutritional stress can be observed.

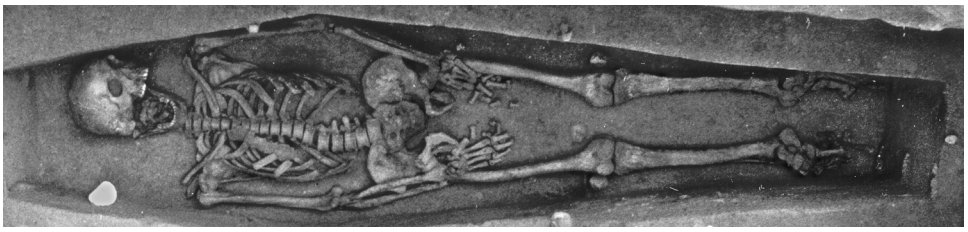

Burial 380

Male aged 40–60 years. Individual has lower- and upper-limb periostitis. Numerous enthesopathies and muscle attachments with significant hypertrophies can be observed. Mild to moderate osteoarthritis affects nearly all of the appendicular joints. Schmorl's nodes and osteophytosis of the sacrum are present. Healed porotic hyperostosis indicative of nutritional stress can also be observed. There is also evidence of femoral/tibial bowing associated with rickets.



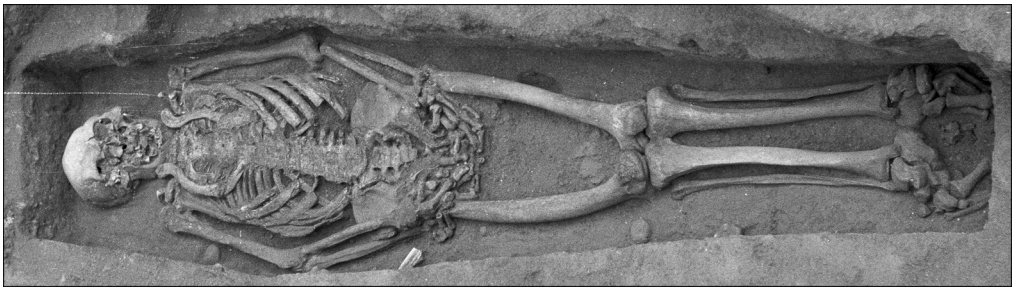

Burial 381

Empty shaft. (No photograph.)

Burial 382

Child aged 4–5 years. Diploic expansion indicative of nutritional stress is present.

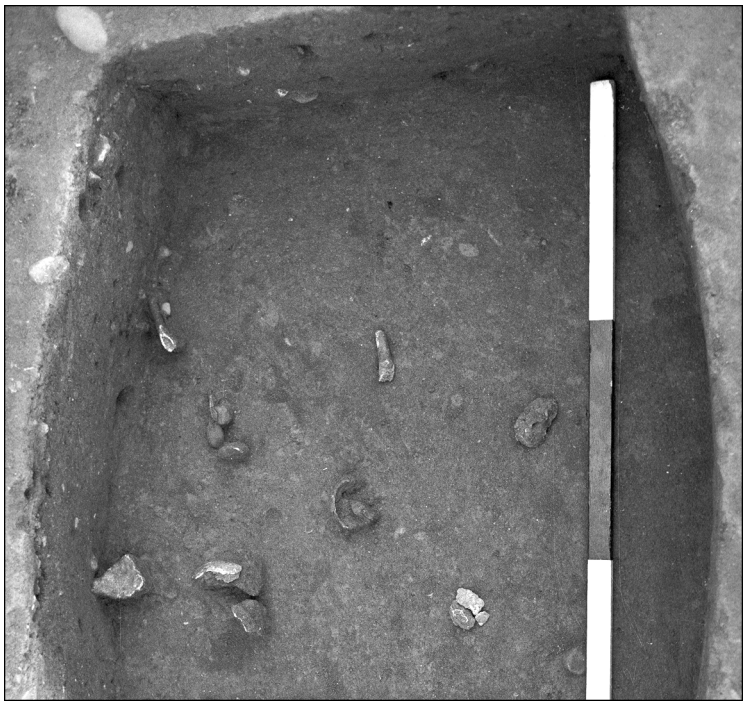

Burial 383

Female aged 14–18 years. Individual has cranial and lower- and upper-limb periostitis. Numerous enthesopathies and muscle attachments with significant hypertrophies, particularly in the upper limbs, are present, as are lumbar Schmorl's nodes. Hypoplasia indicators of childhood stress are also present.

Burial 384

Female aged 25–45 years. Periostitis of the lower and upper limbs is present. Significant muscle attachments with hypertrophies are found on the femora and occipital. Also present is evidence of cervical osteophytosis. Sr isotope analysis suggests birth in the Americas/New York.



Burial 385

Female aged 40–60 years. Individual has periostitis of the lower limbs. Numerous enthesopathies and muscle attachments with significant hypertrophies are present. Mild to severe osteoarthritis affects nearly all axial and appendicular joints. Schmorl's nodes, spondylolysis, and osteophytosis are present. Healed porotic hyperostosis indicative of nutritional stress can also be observed. There is also evidence of femoral/tibial bowing associated with rickets.

Burial 386

Infant aged 0–.30 years.

Burial 387

Male aged 34–44 years.

Burial 388

Female aged 27–57 years. Lower- and upper-limb periostitis is evident. Numerous enthesopathies and significant muscle-attachment hypertrophies are present. Mild to moderate osteoarthritis affects many of the appendicular joints and the temporomandibular joint. Healed porotic hyperostosis and diploic expansion indicative of nutritional stress can be observed.



Burial 389

Female of indeterminate age. Hypoplastic indicators of childhood stress are present.

Burial 390

Male aged 25–35 years. There is evidence of lower- and upper-limb periostitis. Observable are femoral enthesopathies and significant muscle-attachment hypertrophies on the femora and humeri. Mild osteoarthritis affects the hip and knee.

Burial 391

Male aged 16.5–19.5 years.

Burial 392

Male aged 42.5–52.5 years.

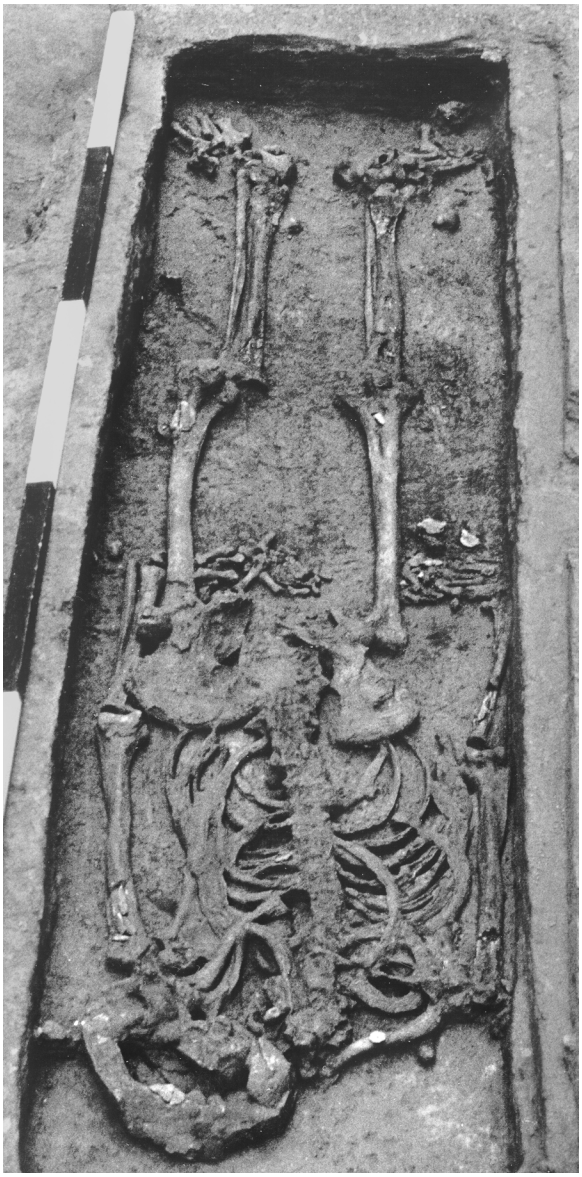

Burial 393

Infant aged -0–.17 years.

Burial 394

Adult 16–25 years.

Burial 395

Male aged 43–53 years. Individual has periostitis of the lower limbs, numerous enthesopathies, and significant muscle-attachment hypertrophies. Mild to severe osteoarthritis affects many of the appendicular joints.

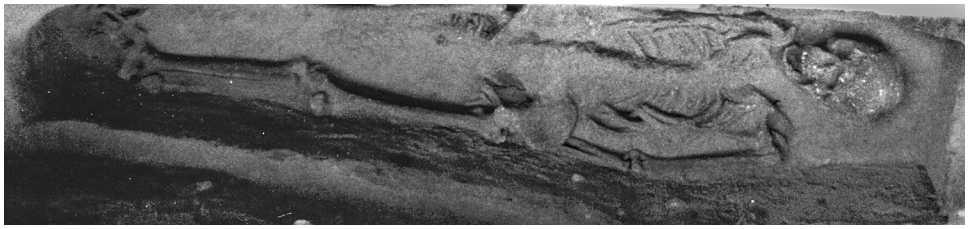

Burial 396

Subadult aged 6.5–8.5 years. Cranial and lower- and upper-limb periostitis is observable.

Burial 397

Female aged 30–40 years. Individual has lower-limb periostitis. Individual has enthesopathies of the tibiae and several significant muscle-attachment hypertrophies throughout the skeleton. Mild osteoarthritis affects the vertebrae and upper limbs with lumbar Schmorl's nodes.

Burial 398

Adult aged 25–35 years. Diploic expansion and healed porotic hyperostosis indicative of nutritional stress can be observed.

Burial 399

Infant aged 0–.30 years.



Burial 400

Male aged 25–34.9 years. The individual has several enthesopathies and significant muscle-attachment hypertrophies. Mild osteoarthritis affects the foot, ankle and shoulder. Diploic expansion indicative of nutritional stress can be observed.

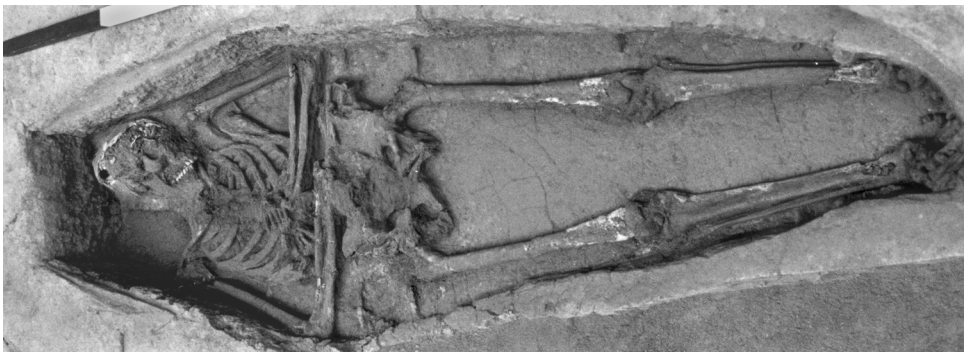

Burial 401

Age and sex indeterminate.



Burial 402

Age and sex indeterminate.

Burial 403

Male aged 39–65 years. Individual has mild osteoarthritis, which affects occipital condyles and temporomandibular joints. Healed porotic hyperostosis indicative of nutritional stress can be observed.



Burial 404

Female of indeterminate age. Periostitis of the lower limbs is evident.

Burial 405

Child aged 6–10 years. Linea aspera and gluteal and brachialis attachments are well developed. Trace ESA clustering not clearly suggestive of natality. High Pb concentration suggests birth in the Americas/New York.

Burial 406

Infant aged 0–4.1 years. Diploic expansion indicative of nutritional stress can be observed.

Burial 407

Age and sex indeterminate.



Burial 408

Male of indeterminate age. Femora have enthesopathies, muscle-attachment hypertrophy, and mild osteoarthritic changes at the distal articular surface. (No photograph.)

Burial 409

Age and sex indeterminate. (No photograph.)

Burial 410

Female of indeterminate age. Periostitis of the lower limbs is evident.

Burial 411

Empty shaft. (No photograph.)

Burial 412

Perinatal infant.

Burial 413

Female aged 50–70 years. There is evidence of osteomyelitis and lower- and upper-limb periostitis. The skeleton has numerous enthesopathies and significant muscle-attachment hypertrophies. Mild to severe osteoarthritis affects many of the appendicular joints. Osteophytosis and myositis ossificans of the ribs are present. Diploic expansion indicative of nutritional stress can be observed.

Burial 414

Male aged 39–59 years. Individual has enthesopathies and significant muscle-attachment hypertrophies on the humeri and ulnae. Moderate to severe osteoarthritis affects the upper-limb joints, knee and vertebral joints. There is evidence of vertebral osteophytosis, and both sacroiliac joints are ankylosed.

Burial 415

Male aged 35–55 years. Individual has numerous enthesopathies and muscle attachments with significant hypertrophies. Mild to moderate osteoarthritis affects the knee and elbow. Cervical osteophytes and Schmorl's nodes are present. There is also evidence of femoral/tibial bowing associated with rickets.

Burial 416

Age and sex indeterminate.



Burial 417

Child/adolescent aged 9.5–14.5 years.

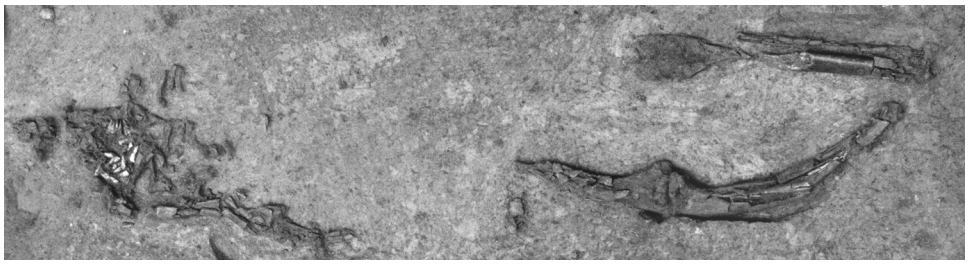

Burial 418

Male aged 30–55 years. Periostitis of the lower and upper limbs, saber shins, and possible treponemal disease are evident. Several enthesopathies and significant muscle-attachment hypertrophies are present. Mild to moderate osteoarthritis affects the vertebrae, ankle, foot, and hand ; osteophytosis is also present. Healed porotic hyperostosis indicative of nutritional stress can be observed.

Burial 419

Male aged 48–62 years. There is evidence of periostitis of the lower limbs. The individual has several enthesopathies and significant muscle-attachment hypertrophies. Mild to moderate osteoarthritis affects axial and appendicular joints. Osteophytosis is present throughout the vertebral column. Diploic expansion indicative of nutritional stress can also be observed. There is also evidence of femoral/tibial bowing associated with rickets.

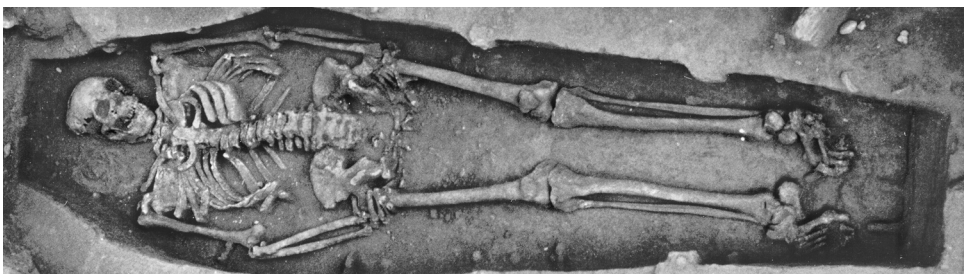

Burial 420, 420.1, 420.2

Separate individuals are not identifiable from the photograph.
Male aged 35–45 years. Individual has numerous enthesopathies and significant muscle-attachment hypertrophies. Mild to moderate osteoarthritis affects several axial and appendicular joints. Cervical and thoracic osteophytosis is present.

Subadult of undetermined age.

Adult of indeterminate age and sex.

Burial 421

Empty shaft.

Burial 422

Empty shaft.

Burial 423

Empty shaft. (No photograph.)

Burial 424

Adult of indeterminate sex and age.

Burial 425

Remained in situ. Probable female over 30 years of age, based on field assessment.

Burial 426

Empty shaft.

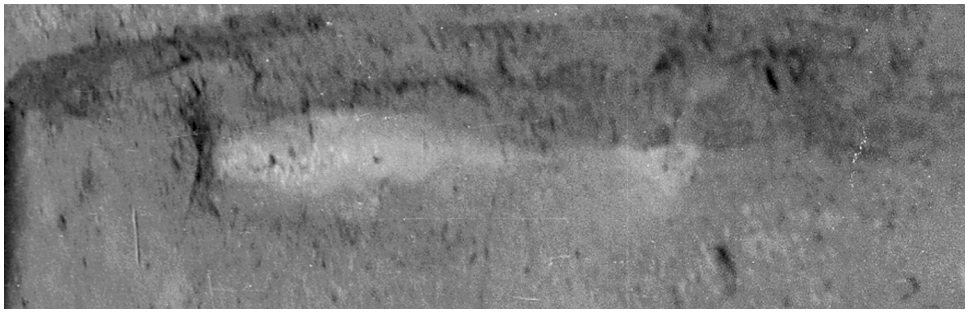

Burial 427

Male aged 16–20 years. Evidence of lower- and upper-limb periostitis is observable. The individual has a moderate number of enthesopathies and significant muscle-attachment hypertrophies.

Burial 428

Female aged 40–70 years. Individual has several enthesopathies and significant muscle-attachment hypertrophies on the humeri. Mild to moderate osteoarthritis affects the shoulders, cervical vertebrae, and temporomandibular joints. Cervical osteophytosis is also present.

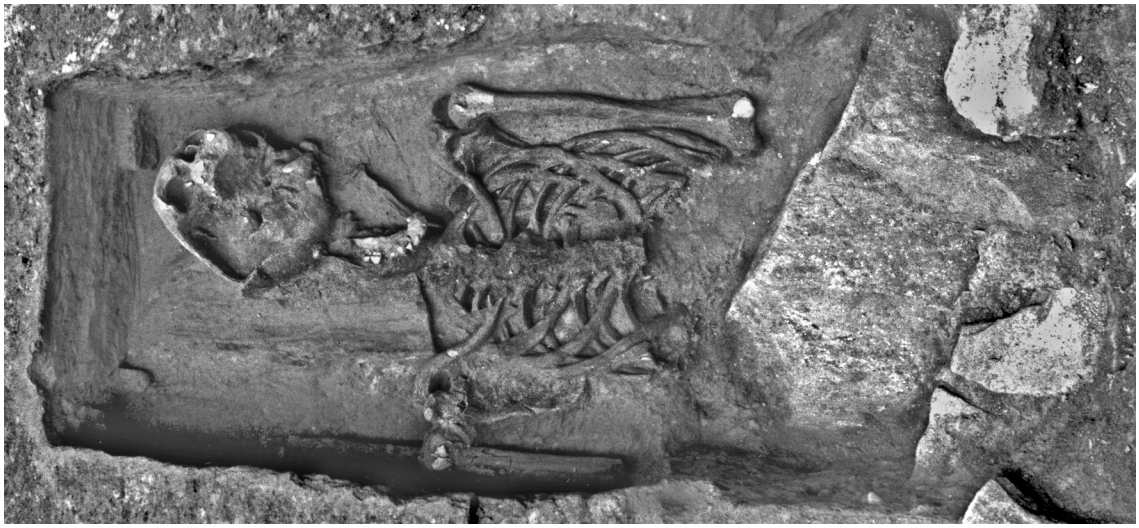

Burial 429

Age and sex indeterminate.

Burial 430

Empty shaft. (No photograph.)

Burial 431

Adult of indeterminate age and sex. Periostitis of the lower limbs is evident.

Burial 432

Adult of indeterminate age and sex.

Burial 433

Adult of indeterminate age and sex. (No photograph.)

Burial 434

Age and sex indeterminate.

Burial 435

Age and sex indeterminate.



Burial 436

Age and sex indeterminate.

Note: Hypoplasia and hypocalcification data based on sample of 99 individuals.

Appendix A

RESEARCH DESIGN SUBCOMMITTEE STATEMENT
AND
ABG PHYSICAL ANTHROPOLOGICAL PEER REVIEW PANEL REPORT

RESEARCH DESIGN SUBCOMMITTEE

Members: Charlene Dwinn-Vaughn, Dr. Jerome Handler, Joan Maynard, Robert McDonald, Noel Pointer

STATEMENT:

"The African Burial Ground is of unparalleled significance to America's heritage. The investigation of this site involves the excavation and study of 390 ancestral remains, primarily of Africans who died while in bondage during the eighteenth century. It is one of the most important archeological sites in this country today in that it is the earliest large skeletal population ever to be examined through careful scientific excavation. The ancestral remains that have been excavated and those remaining in the ground are also of great spiritual and inspirational significance to the African American community. (Note: throughout this document the term "African American" is used in reference to post-colonial communities of African descent. Historic communities are referred to as "African", "Irish", etc., as appropriate in reference to both first generation and eighteenth-century communities prior to the nation's establishment.

Due to the circumstances that have brought about their presence, these material remains of African ancestors present themselves during a time of social and emotional strife when inspirational uplift is most needed in the African-American community; during a time when evidence of the significance of racism in America needs desperately to be brought to bear on the minds of Euro-Americans; and during a time when there is a thirst for knowledge about African heritage that has propelled heated debates about in adequacies of American education. These African ancestral remains have presented both a challenge and an opportunity to simultaneously address these issues.

This Research Design also recognizes the necessity of ongoing consultation with religious leaders who will work with scientists and others to see to the sacred aspects of this important project. Periodic religious ceremonies are anticipated throughout the project. Ultimately, an appropriately dignified reburial should take place at a site designated by the descendant community and the city of New York. In addition, plans for a memorial and world-class museum should be realized. The wealth of information that these african ancestors provide deserves nothing less as a platform from which through science, they may speak to us about the place that they came from, the physical evidence of their struggles in this "New World," and the culture they clung to and created here. It is fervently hoped that the implementation of this Research Design will bring this important spiritual, cultural, and scientific resource into the prominence that it deserves.

Research Design SubCommittee
June 14, 1993

African Burial Ground Committee Meeting May 24, 1993
Proposed Resolution.

The Subcommittee on Research Design recommends as a motion to the Steering Committee the following:

That the Steering Committee accept the Research Design submitted to GSA on April 22, 1993.

That the Steering Committee agree that this is a bona fide scholarly and scientific document which offer a professionally competent plan for the study and analysis of the skeletal remains and related archeological and historical issues.

The Steering Committee has confidence in the professional abilities of Dr. Blakely, as Director of the project will have full authority to resolve issues related to the scientific methodologies, analytical procedures, and similar issues related to the overall research design.

The resolution was accepted.

General Services Administrat
Public Buildings Service
Washington, DC 20405

FOLEY SQUARE AFRICAN BURIAL GROUND PHYSICAL ANTHROPOLOGICAL PEER REVIEW PANEL REPORT

I. STATEMENT OF PURPOSE:

The purpose of this panel was to evaluate the "Scope of Work for the Cleaning, Consolidation, and Stabilization of the Human Remains from the African Burial Ground, New York City." The panel met for the express purpose of collecting data and to receive briefings from the projects Scientific Director, the archaeological consultants, and GSA managers. The panel visited the present storage facility at Lehman College to view the condition of the human skeletal remains and were briefed on the proposed conservation protocol.

II. RESEARCH OBJECTIVES:

Based on these briefings and our review of all relevant documentation we identified the following community established research objectives :

1. To gather biocultural data to better understand the culture, history, living conditions and circumstances of life of colonial Africans in New York and the diaspora.

2. To insure that such data are collected in a manner that is responsive to the express concerns of the descendent community, which include:

   a. *All scientific research be conducted at Howard University;*

   b. *That the research should be directed by African American professionals, and offer educational opportunities for African American students and others;*

   c. *That reinterrment occur at the earliest possible time.*

III. CONSERVATION ISSUES:

The scope of work was evaluated within the context of the community established research objectives. This evaluation resulted in the panel identifying conservation and professional ethical issues.

Federal Recycling Program Printed on Recycled Paper

Conservation issues:

1. The proposed conservation scope of work statement is inconsistent with the scientific research objectives, as outlined above;

2. The proposed conservation would result in an extreme delay in the transfer of the human skeletal remains to Howard University.

3. The proposed conservation procedures would result in an unconscionable delay in the reinterrment of the human remains;

Professional ethical issues:

1. We agree with the scope of work that the highest possible professional and ethical standards should be maintained in transportation and subsequent analysis of the human remains;

2. We have reviewed the "Bylaws of the American Institute for Conservation of Historic and Artistic Works, Inc." which is cited in the scope, as the standard that should be adhered to for the preparation of the human skeletal remains for transfer to Howard University;

3. These bylaws establish measures that are clearly inappropriate to the preparation of human remains for analysis prior to reinterrment; they address the conservation of historic and artistic objects;

4. The preparation of human remains for physical anthropological analysis must be informed by a cognizance of significant anatomical features and a knowledge of relevant research questions; this knowledge is only possessed by a physical anthropologist with training and research experience in biocultural studies;

5. The preparation of the human remains for the physical anthropological analysis should be conducted in compliance with the standard physical anthropological practices and the ethical principles of the American Anthropological Association;

6. Decisions to be made concerning the steps for the preparation and transport of human remains must be made in a manner consistent with the maximization of physical anthropological data retrieval;

IV. SUMMARY OF CONSIDERATIONS:

Based on these considerations, it is the view of the panel, which includes physical anthropologists, with considerable practical experience in the transportation of

humans remains, that immediate relocation of the human skeletal remains to Howard University would result in minimal data loss.

The panel, which includes an historical archaeologist, further concurs that the project's principal archaeological investigator, has considerable experience with burial ground excavations and has been and could continue to be instrumental to this process of documenting and excavating the pedastalled human skeletal material.

V. RECOMMENDATIONS:

In view of foregoing, the entire panel strongly recommends the African Burial Ground human skeletal remains be appropriately packed and shipped to Howard University within 60 days.

We wholeheartedly support the African American communities' desire that the scientific research be conducted at Howard University. Howard University is the only American university that has a large, well documented African American osteological collection and a nationally recognized faculty with expertise in the interpretation of African American history and culture.

Finally, the panel recommends that all decisions concerning this transfer should be made by the physical anthropologist, Dr. Michael Blakey, the Project Scientific Director. This will greatly facilitate the timely analysis and reinterrment of this extraordinarily important human skeletal population.



Dr. Phillip Walker
Department of Anthropology
University of California Santa Barbara

Dr. Carrel Cowan-Ricks
Historical Archeologist
Clemson University

Dr. Ted Rathbun
Anthropology Department
University of South Carolina

Dr. Eleanor Mason Ramsey
President
Mason Tillman Associates, Ltd.

Dr. Clark Larsen
Department of Sociology and
Anthropology
Purdue University

humans remains, that immediate relocation of the human skeletal remains to Howard University would result in minimal data loss.

The panel, which includes an historical archaeologist, further concurs that the project's principal archaeological investigator, has considerable experience with burial ground excavations and has been and could continue to be instrumental to this process of documenting and excavating the pedastalled human skeletal material.

V. RECOMMENDATIONS:

In view of foregoing, the entire panel strongly recommends the African Burial Ground human skeletal remains be appropriately packed and shipped to Howard University within 60 days.

We wholcheartedly support the African American communities' desire that the scientific research be conducted at Howard University. Howard University is the only American university that has a large, well documented African American osteological collection and a nationally recognized faculty with expertise in the interpretation of African American history and culture.

Finally, the panel recommends that all decisions concerning this transfer should be made by the physical anthropologist, Dr. Michael Blakey, the Project Scientific Director. This will greatly facilitate the timely analysis and reinterrment of this extraordinarily important human skeletal population.

Dr. Phillip Walker
Department of Anthropology
University of California Santa Barbara

Dr. Ted Rathbun
Anthropology Department
University of South Carolina

Dr. Clark Larsen
Department of Sociology and
Anthropology
Purdue University

Dr. Carrel Cowan-Ricks
Historical Archeologist
Clemson University

Dr. Eleanor Mason Ramsey
President
Mason Tillman Associates, Ltd.

humans remains, that immediate relocation of the human skeletal remains to Howard University would result in minimal data loss.

The panel, which includes an historical archaeologist, further concurs that the project's principal archaeological investigator, has considerable experience with burial ground excavations and has been and could continue to be instrumental to this process of documenting and excavating the pedastalled human skeletal material.

V. RECOMMENDATIONS:

In view of foregoing, the entire panel strongly recommends the African Burial Ground human skeletal remains be appropriately packed and shipped to Howard University within 60 days.

We wholeheartedly support the African American communities' desire that the scientific research be conducted at Howard University. Howard University is the only American university that has a large, well documented African American osteological collection and a nationally recognized faculty with expertise in the interpretation of African American history and culture.

Finally, the panel recommends that all decisions concerning this transfer should be made by the physical anthropologist, Dr. Michael Blakey, the Project Scientific Director. This will greatly facilitate the timely analysis and reinterrment of this extraordinarily important human skeletal population.

Dr. Phillip Walker
Department of Anthropology
University of California Santa Barbara

Dr. Carrel Cowan-Ricks
Historical Archeologist
Clemson University

Dr. Ted Rathbun
Anthropology Department
University of South Carolina



Dr. Clark Larsen
Department of Sociology and
Anthropology
Purdue University

Dr. Eleanor Mason Ramsey
President
Mason Tillman Associates, Ltd.

humans remains, that immediate relocation of the human skeletal remains to Howard University would result in minimal data loss.

The panel, which includes an historical archaeologist, further concurs that the project's principal archaeological investigator, has considerable experience with burial ground excavations and has been and could continue to be instrumental to this process of documenting and excavating the pedastalled human skeletal material.

V. RECOMMENDATIONS:

In view of foregoing, the entire panel strongly recommends the African Burial Ground human skeletal remains be appropriately packed and shipped to Howard University within 60 days.

We wholeheartedly support the African American communities' desire that the scientific research be conducted at Howard University. Howard University is the only American university that has a large, well documented African American osteological collection and a nationally recognized faculty with expertise in the interpretation of African American history and culture.

Finally, the panel recommends that all decisions concerning this transfer should be made by the physical anthropologist, Dr. Michael Blakey, the Project Scientific Director. This will greatly facilitate the timely analysis and reinterrment of this extraordinarily important human skeletal population.

Dr. Phillip Walker
Department of Anthropology
University of California Santa Barbara

Carrel Cowan-Ricks

Dr. Carrel Cowan-Ricks
Historical Archeologist
Clemson University

Dr. Ted Rathbun
Anthropology Department
University of South Carolina

Dr. Clark Larsen
Department of Sociology and
Anthropology
Purdue University

Dr. Eleanor Mason Ramsey
President
Mason Tillman Associates, Ltd.

humans remains, that immediate relocation of the human skeletal remains to Howard University would result in minimal data loss.

The panel, which includes an historical archaeologist, further concurs that the project's principal archaeological investigator, has considerable experience with burial ground excavations and has been and could continue to be instrumental to this process of documenting and excavating the pedastalled human skeletal material.

V. RECOMMENDATIONS:

In view of foregoing, the entire panel strongly recommends the African Burial Ground human skeletal remains be appropriately packed and shipped to Howard University within 60 days.

We wholeheartedly support the African American communities' desire that the scientific research be conducted at Howard University. Howard University is the only American university that has a large, well documented African American osteological collection and a nationally recognized faculty with expertise in the interpretation of African American history and culture.

Finally, the panel recommends that all decisions concerning this transfer should be made by the physical anthropologist, Dr. Michael Blakey, the Project Scientific Director. This will greatly facilitate the timely analysis and reinterrment of this extraordinarily important human skeletal population.

Dr. Phillip Walker
Department of Anthropology
University of California Santa Barbara



Dr. Carrel Cowan-Ricks
Historical Archeologist
Clemson University

Dr. Ted Rathbun
Anthropology Department
University of South Carolina

Dr. Clark Larsen
Department of Sociology and
Anthropology
Purdue University

Dr. Eleanor Mason Ramsey
President
Mason Tillman Associates, Ltd.

Appendix B

NEW YORK AFRICAN BURIAL GROUND PROJECT
SKELETAL ANALYSIS FORMS

FILE CONTENTS:

Burial# 101
Catalog# 843

PRESENT	MISSING DATA		
✓		1	Field Photograph
✓		2	Field Assessment
		3	Burial Form
		4	Provenience Sheet
		5	Field Sketch
✓		6	Packing Inventory
✓		7	Packing Inventory Photos
✓		8	Condition Report
✓		9	Condition Report Photos
✓		10	Skeletal Inventory
✓		11	Anthropometric Record (adult)
N/A		12	Epiphyseal Closure (subadult)
N/A		13	Immature Measurement (subadult)
✓		14	Dental Inventory
✓		15	Dental Measurement (2 for mixed dentition)
✓		16	Dental Morphology
✓		17	Dental Pathology (3 forms)
✓		18	Age Determination
✓		19	Sex Determination
✓	✓	20	Pathological Assessment mc#
✓		21	Artifact Location Map
		22	Feature Sketches
✓		23	Photographic Record *
✓		24	Additional Forms (listed below)

Pathology lesion Homunculi (back)
Packing list
Age Assessment by OT
DNA specimen information
Histology sample information

COMMENTS:

* Complete but needs to be transcribed to Ph. Record Form

85

HERBERT H. LEHMAN [illegible] #: 101

MFAT
Metropolitan Forensic Anthropology Team
at Lehman College
Field Notes
Broadway-Foley Square Black Cemetery Site

RECEIVED
'92 OCT 8 AM 9:24

p. 1 of 4

IN SITU SKELETAL INSPECTIONAL ANALYSIS

Burial #: 101
Catalogue #: 843
Block #: 154

HERBERT [illegible]

DATE: 18 Dec. 1991

ASSESSOR/S: L. Eisenberg / G. Hess
EXCAVATOR/S: C. Gross / B. Ludwig

CONDITION OF REMAINS:

Excellent preservation, burial fully articulated. Fully extended, head at west. Feet up against end of coffin - bones collapsed vertically. Hands were extended along top of femur, left fell in between rt. outside of femurs. - now fingers parallel to femurs. Skull still articulated, upright & frontal is did not fall to side. Shroud pin stain - cor. suture. Another stain across T7 & 8. Sternum present but fallen to left. Rt. clavicle disartic. Patellae slipped off to left. - some disturbance, but minor. Post mortem damage to several rib ends & sup. ramus of lt. pubis. Long. crack in sacrum.

Human cranial frag. foreign to this individual. Adjacent to prox. end of rt. tibia. 2 bone buttons - one midshaft other distal end of rt. femur.

A fairly tight fit in coffin - head & feet against ends. Some "shrugging" at shoulders. Rt humerus prox. tilted up against coffin wall - stuffed in, this one!

Right lunate laying on right rib area

SKULL: **Present (✓)** ✓ **Braincase:** **Condition** EXCELLENT

POST-MORT. DAMAGE TO LEFT ORBIT

RI1: SMALL CIRCULAR CARIES (?) ON BUCCAL SURFACE

LC: BROKEN
LP1: MISSING. P-M
LP2: EXTREME OBLIQUE WEAR
LM1 MISSING. P-M
LM3 NOT VISIBLE

	Present (✓) Right	Left	Decid.	Perm
I1	✓	✓		✓
I2	✓	✓		✓
C	✓	✓		✓
P1	✓			✓
P2	✓	✓		✓
M1	✓			✓
M2	✓	✓		✓
M3	✓	?		✓

Mandible: **Present (✓)** ✓ **Condition** EXCELLENT

LM1,2,3 : NOT VISIBLE
RP2 BROKEN

	Present (✓) Right	Left	Decid.	Perm
I1	✓	✓		✓
I2	✓	✓		✓
C	✓	✓		✓
P1	✓	✓		✓
P2	✓	✓		✓
M1	✓(?)	?		✓
M2	✓	?		✓
M3	✓	?		✓

NYAT Field Notes
By: LE & GH (initials)
In Situ Skeletal Assessments

Burial #: 101
p. 2 of 4

Vertebrae:
Cervical: NOT EXPOSED
Thoracic: ALL TWELVE
Lumbar: ALL FIVE
Sacrum: ALL FIVE - VERT. FRACTURE LAT. TO MIDLINE LOWER END OF VENTRAL FACE CRUSHED P-M
Coccyx: PRESENT (?)

Sternum: PRESENT - EXCELLENT CONDITION XIPHOID PROCESS IS PRESENT.

Ribs: ALL TWELVE BOTH SIDES DISTAL ENDS DAMAGED. POST MORTEM

		Present (✓)	Condition:
Clavicle	Right	✓	EXCELLENT NO DAMAGE
	Left	✓	EXCELLENT " "
Scapulae	Right	✓	"
	Left	✓	"
Innominates	Right	✓	"
	Left	✓	" RAMUS DAMAGED. POST MORTEM & ISCHIUM BRO

Upper Limb:

Humerus	Right	✓	"
	Left	✓	"
Ulna	Right	✓	"
	Left	✓	"
Radius	Right	✓	"
	Left	✓	"
Hand: Carpals:		APPARENTLY	ALL PRESENT NOT VISIBLE
Metacarpals:		"	" " " "
Phallanges:		"	" " " "

Lower Limb:

Femur	Right	✓	EXCELLENT
	Left	✓	"
Patella	Right	✓	"
	Left	✓	SOME DAMAGE P-M DISTAL END?
Tibia	Right	✓	EXCELLENT PATHOLOGY?
	Left	✓	" "
Fibula	Right	✓	"
	Left	✓	DAMAGE TO PROX. END P-M
Foot: Tarsals:		APPARENTLY	ALL PRESENT NOT VISIBLE
Metatarsals:		"	" " " "
Phallanges:		"	" " " "

MFAT Field Notes
By: LE /OH (initials)
In Situ Skeletal Assessments

Burial #: 101
p. 3 of 4

IN SITU MEASUREMENTS:	SIDE	DIMENSION	On board
Maximum Lengths:			
Humerus:	L	365	L 367
	R	374	R 375
Radius:	L	270	L 271
	R	NOT ACCESSIBLE	
Innominate/Ilium:	L	ISCHIUM BROKEN	
	R	214	
Femur:	L	490	Femur L. 506
	R	480	Femur R 497
Tibia:	L	431	Tibia R 434
	R	431	Tibia L 437
Femoral Circumference: (@ mid-shaft)	L	98	FEMORAL HEAD DIA. L 50
			R 50
Innominate/Ilium Width:			

SEX ASSESSMENTS

Skull: MASTOIDS DIFFICULT TO SEE GIVEN SKULL POSITION - APPEAR MEDIUM TO LARGE. SUPRA ORBITAL MARGIN SHARP W. SOME ROUNDING. SLIGHTLY RAISED AREA OVER GLABELLA. BACK OF SKULL NOT VISIBLE. MANDIBLE SYMPHYSEAL HEIGHT IS GREAT AS WIDTH OF ASCENDING RAMUS.
SKULL APPEARS "SMALLISH" COMPARED TO POST-CRANIAL SKELETON.

Innominate: SCIATIC NOTCH APPEARS NARROW, "J SHAPED"
NO PRE-AURICULAR SULCUS APPARENT
VENTRAL ARC APPARENTLY NARROW

Sacrum: MIDDLE WIDER THAN EITHER OF THE ALAE

Femur: APPEAR ROBUST W. LG. HEADS & VERY WIDE CONDYLAR BREADTH
FEMUR LENGTHS 480 & 490 FEMURAL CIR. 98 & HEAD DIA. 50
Other: GENERALLY LG. POST-CRANIAL SKELETON

Tentative Conclusion: MALE

NYAT Field Notes
By: LE/CH (initials)
In Situ Skeletal Assessments

Burial #: 101
p. 4 of 4

RACE ASSESSMENTS

Skull: SQUARE ORBITS
WIDEST POINT OF SKULL AT BACK
NASAL MODERATELY WIDE BUT AREA AROUND NASION IS BROAD
MODERATE TO PRONOUNCED PROGNATHISM.

Tentative Conclusion: BLACK

AGE ASSESSMENTS

Teeth: M3 S ERUPTED OCCLUSAL SURFACES NOT VISIBLE

Vertebral Lipping: NO APPARENT LIPPING

Other: ALL EPIPHYSES FUSED, CORONAL SUTURE LARGELY FUSED ECTOCRANIAL
TENTATIVE CONCLUSION: ADULT : 30-35 ?

PATHOLOGIES/ANOMALIES

- TRAUMA (?) / P-M BREAK? RIGHT SIDE OF MANDIBLE INFERIOR P2.
- BILATERAL PRESENCE OF OS ACROMIALE - ACTIVITY RELATED?
- BILATERAL ENLARGEMENT OF ANTERIOR MARGINS OF TIBIAE. NEW BONE APPOSITION IS WELL CONSOLIDATED W/ UNDERLYING CORTICAL BONE. (METABOLIC? INFECTIOUS?) FIBULAE LOOK CLEAR.

SPECIAL NOTES/COMMENTS: EXCAVATOR NOTED POSSIBLE RODENT BURROW. MAY ACCOUNT FOR MINOR DISTURBANCES.

THE AFRICAN BURIAL GROUND SKELETAL POPULATION

Packing List

BURIAL 101

Container #: 4

Prepared By: JM Shipment Date: / / 93

Room Temp.: °F Room RH: %

Accession Numbers:

101.9 → 101.20

TOTAL NUMBER OF PIECES IN CONTAINER: 12

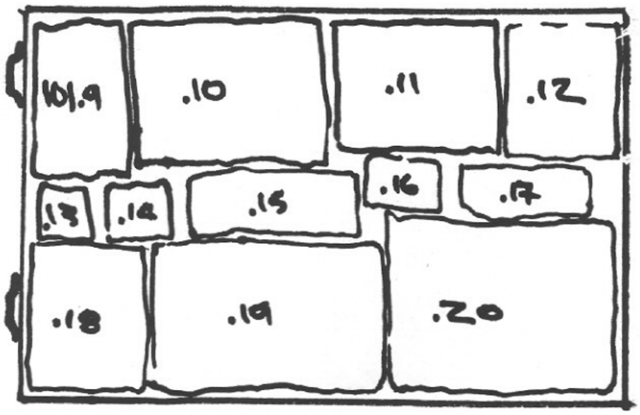

THE AFRICAN BURIAL GROUND SKELETAL POPULATION

Packing List

BURIAL 101

Container #: 3

Prepared By: JM

Shipment Date: __/__/ 93

Accession Numbers:

101.3 → 101.8

TOTAL NUMBER OF PIECES IN CONTAINER: 6

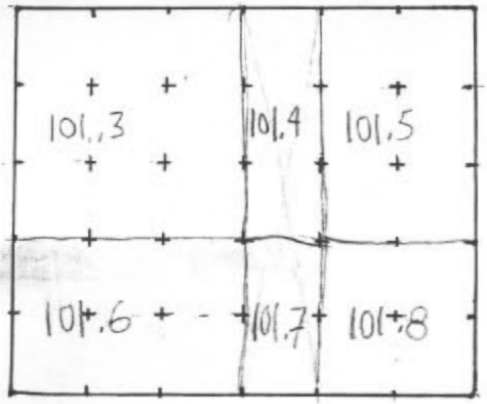

THE AFRICAN BURIAL GROUND SKELETAL POPULATION

Packing List

BURIAL 101

Container #: 6

Prepared By: _____

Shipment Date: ___/___/ 93

Accession Numbers:

101.31 → 101.43

TOTAL NUMBER OF PIECES IN CONTAINER: 13

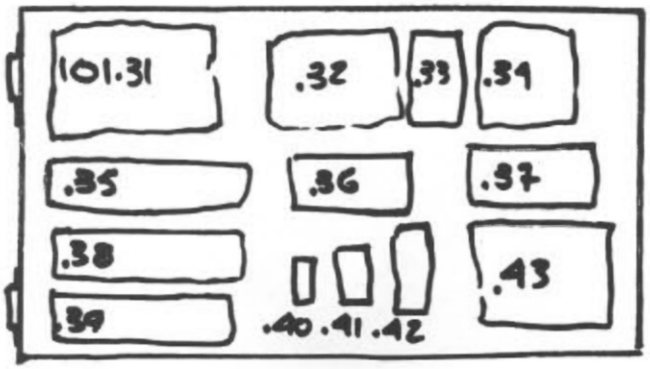

SOCIAMNTH. DEPT. TD:202-606-4695 SEP 01 93 13:39 NO.001 P.02

African Burial Ground
Packing Inventory

Burial # 101 Date 9/23/93 +20

CRANIAL MATERIAL ____ Packer Jim cranium packed by Sigmund or Ron

L	R	Bone	Single Bones	Dentition	Maxilla L	Maxilla R	Mandible L	Mandible R
	✓	Mandible	Occipital					
		Frontal	Sphenoid					
		Parietal	Ethmoid	I1				
		Temporal	Vomer	I2				
		Zygomatic	Hyoid	C				
		Lacrimal		P1				
		I.N.C.		P2				
		Nasal	✓ Cranium	M1				
		Maxilla		M2				
		Palatine		M3				
		Malleus		Supernumerary Dentition				
		Incus						
		Stapes						

AXIAL POSTCRANIAL ____

Number	Element
	Cervical Vertebrae
✓	Thoracic Vertebra
✓	Lumbar Vertebrae
✓	Sacrum
	Coccyx
✓	Sternum
✓	Ribs
	General Thoracic

APPENDICULAR POSTCRANIAL ____

L	R	Bone	L	R	Bone
✓	✓	Clavicle			Ilium
✓	✓	Scapula			Ischium
✓	✓	Humerus			Pubis
✓	✓	Radius	✓	✓	Femur
✓	✓	Ulna	✓	✓	Patella
			✓	✓	Tibia
				✓	Fibula
			L		Innominate

Extremities

Number	Element	Number	Element
	Carpals		Tarsals
	Metacarpals		Metatarsals
	Carpal Phalanges		Tarsal Phalanges
LR	Hands	LR	Feet

COMMENTS ____

BURIAL 101
101.21 → .36
BOX 05
10 PCS

THE AFRICAN BURIAL GROUND SKELETAL POPULATION

Condition Report

Prepared By: SIGMUND Accession #: 101.2

Burial #: 101 Bx 2 of 2

Catalogue #: 843

Piece Count: _____ of _____

Pedestalled: Y / (N) Soil Type: _____ (E)arth (C)lay/Silt (S)and/Gravel

Biologically Active:
Bones: (Y) / N & Innominate
Soft Tissue: Y / N
Cultural Materials: Y / N

Temperature: _____ °F RH: _____ %

Photo #: _____

Video Tape #: _____ Counter Start: _____

Counter Stop: _____

Contents/Condition: Periosteum loss, drying of clay. Iliac crest zone articulated and of Sacrum separated, Cracking along body of ilium

Cabinet 14 to G

10/1 G > OUT

THE AFRICAN BURIAL GROUND SKELETAL POPULATION

Condition Report

Prepared By: Ron Long Accession #: 101.1

Date: 9 / 20 / 93

Burial #: B-101

Catalogue #: _____ Container #: 1 OF 1

Piece Count: _____ of _____

Pedestalled: Y / (N) Soil Type: N (E)arth (C)lay/Silt (S)and/Gravel

Biologically Active: Y / N
Bones: (Y) / N
Soft Tissue: Y / N
Cultural Materials: Y / N

Photo Nos.: _____

Video Tape #: _____ Counter Start: _____

Counter Stop: _____

Contents/Condition: Skull was Packed upside Down.
Postmortem Dental Lost. Front Teeth Loose

Cabinet Temp: _____ °F Cabinet RH: _____ %

Movement Record:	Cabinet From:	Cabinet To:
9 / 20 / 93	14	G
10 / 1 / 93	G	OUT
/ / 93		
/ / 93		

AFRICAN BURIAL GROUND PROJECT
BIOLOGICAL ANTHROPOLOGY LABORATORY
HOWARD UNIVERSITY

INVENTORY FORM FOR COMPLETE REMAINS

Site Name/Number NYABG / 101 Observer JEL

Feature/Burial Number 101 / Cat. 343 Date

Burial/Skeleton Number 101 /

Present Location of Collection Howard University/ red lab

****

Cranial Bones

	Left	Right		Left	Right
Frontal		1	Malar	1	1
Parietal	1	1	Maxilla	1	1
Occipital		1	Palatine	2	1
Temporal	1	1	Mandible	1	1
TMJ	1	1	Vomer	1	
			INC	1	1
Zthmoid		1			
Lacrimals	1	1			
Nasals	1	1			
Sphenoid					
Malleus	9	9			
Incus	9	9			
Stapes	9	9			

****

Postcranial Bones

	Left	Right			
Clavicle	1	1	Sternum:	Manubrium 1	Body 1
Scapula					
Body	2	2			
Glenoid f.	1	1			

Vertebrae (individual)

	Centrum	Neural Arch
C1	1	2
C2	1	1
C3	1	1
C4	1	1
C5	1	1
C6	1	1
C7	1	3
T1	1	1
T2	1	1
T3	1	1
T4	1	1
T5	1	1
T6	1	1

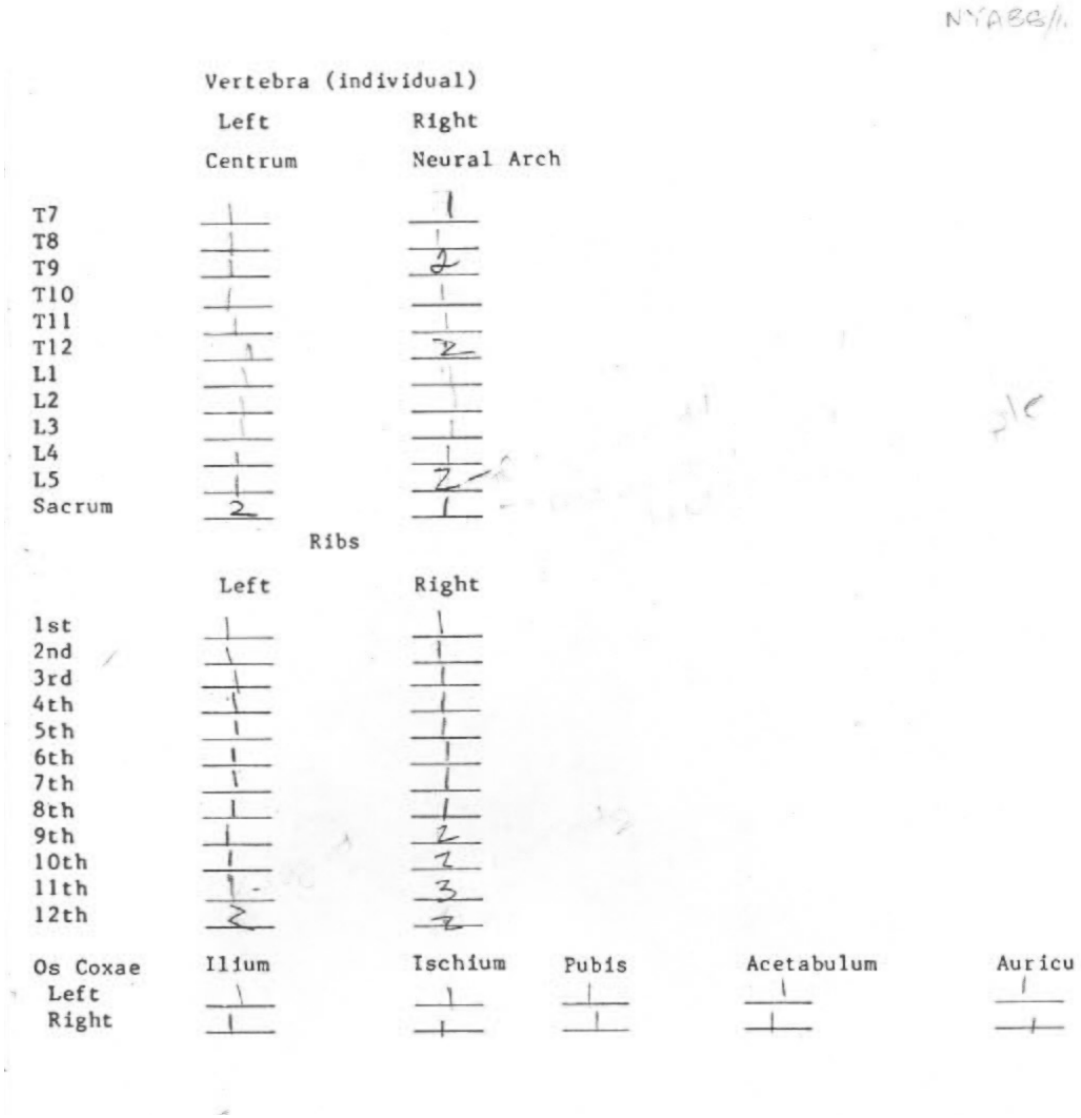

NYABG/1.

Vertebra (individual)

	Left Centrum	Right Neural Arch
T7	1	1
T8	1	1
T9	1	2
T10	1	1
T11	1	1
T12	1	2
L1	1	1
L2	1	1
L3	1	1
L4	1	1
L5	1	2
Sacrum	2	1

Ribs

	Left	Right
1st	1	1
2nd	1	1
3rd	1	1
4th	1	1
5th	1	1
6th	1	1
7th	1	1
8th	1	1
9th	1	2
10th	1	2
11th	1	3
12th	2	2

Os Coxae	Ilium	Ischium	Pubis	Acetabulum	Auricu
Left	1	1	1	1	1
Right	1	1	1	1	1

Series/Burial /Skeleton BT01 cat 843
Observer/Date TEL 9/3

LONG BONES

	Proximal Epiphysis	Proximal Third (Diaphysis)	Middle Third (Diaphysis)	Distal Third (Diaphysis)	Distal Epiphysis
Humerus Left	1	1	1	1	1
Humerus Right	1	1	1	1	1
Radius Left	1	1	1	1	1
Radius Right	1	1	1	1	1
Ulna Left	1	1	1	1	1
Ulna Right	1	1	1	1	1
Femur Left	1	1	1	1	1
Femur Right	1	1	1	1	1
Tibia Left	1	1	1	1	1
Tibia Right	1	1	1	1	1
Fibula Left	—	2	1	1	1
Fibula Right	1	1	1	1	1

	Left	Right	Unsided
Patella	1	1	

	Left	Right	Unsided
Hand # Carpals	8	8	—
#Metacarpals	5	5	—
#Phalanges	12	14	—

	Left	Right	Unsided
Foot Talus	1	1	—
Calcaneus	1	1	
# Tarsals	5	5	—
# Metatarsals	5	5	—
#Phalanges	14	14	—

had 2 sesamoid bones

← had 1 sesamoid bone

COMMENTS: Sacral fragment set aside for DNA analysis

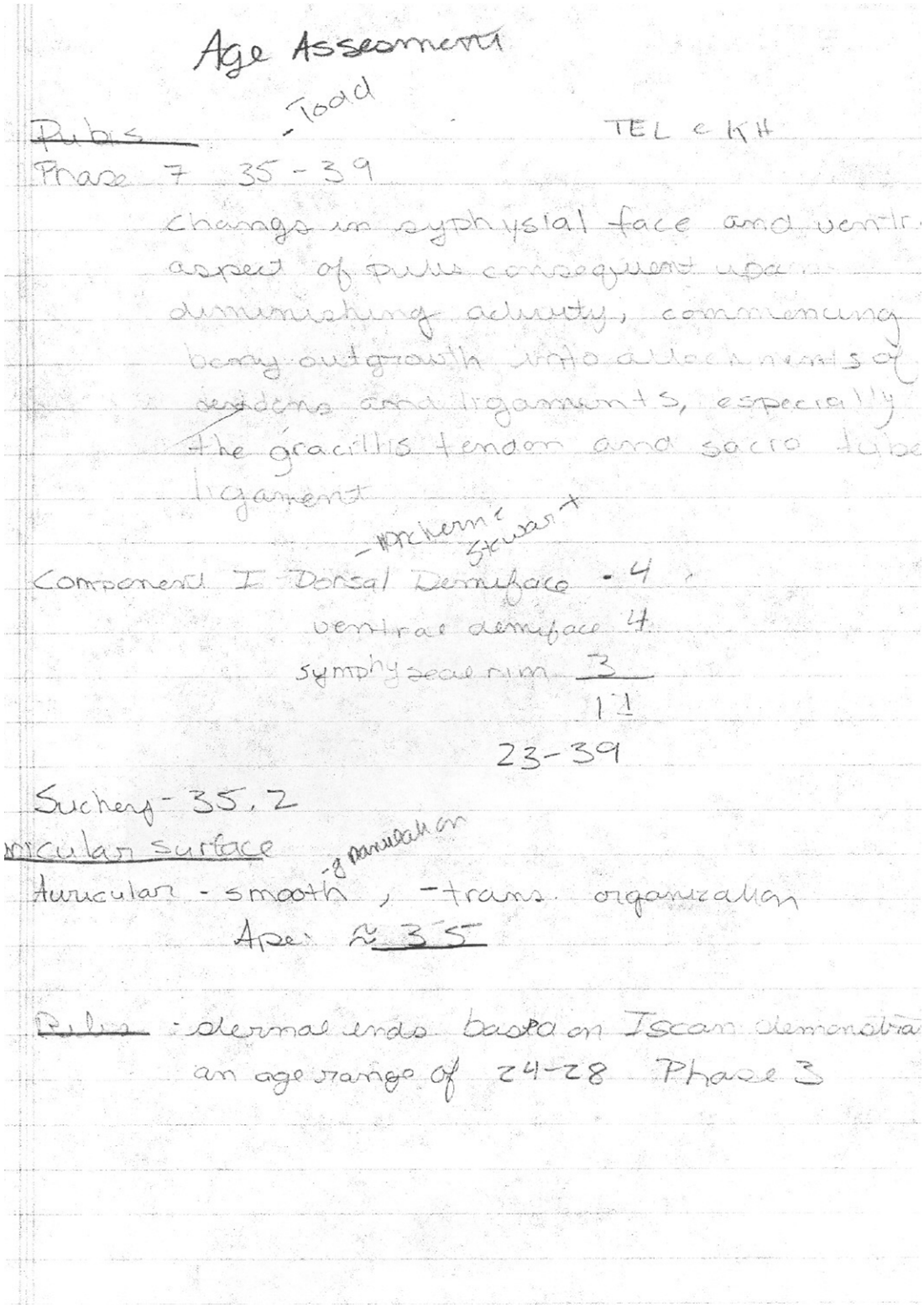

Age Assessment
- Todd

Pubis TEL < KH

Phase 7 35 - 39

Changes in syphysial face and ventral aspect of pubis consequent upon diminishing activity, commencing bony outgrowth into attachments of tendons and ligaments, especially the gracilis tendon and sacro iliac ligament

- McKern & Stewart

Component I: Dorsal Demiface - 4
ventral demiface 4
symphyseal rim 3
11

23-39

Suchey - 35, 2

Auricular surface

Auricular - smooth, - trans. organization
Age: ≈ 35

Pubis: dermal ends based on Iscan demonstrate an age range of 24-28 Phase 3

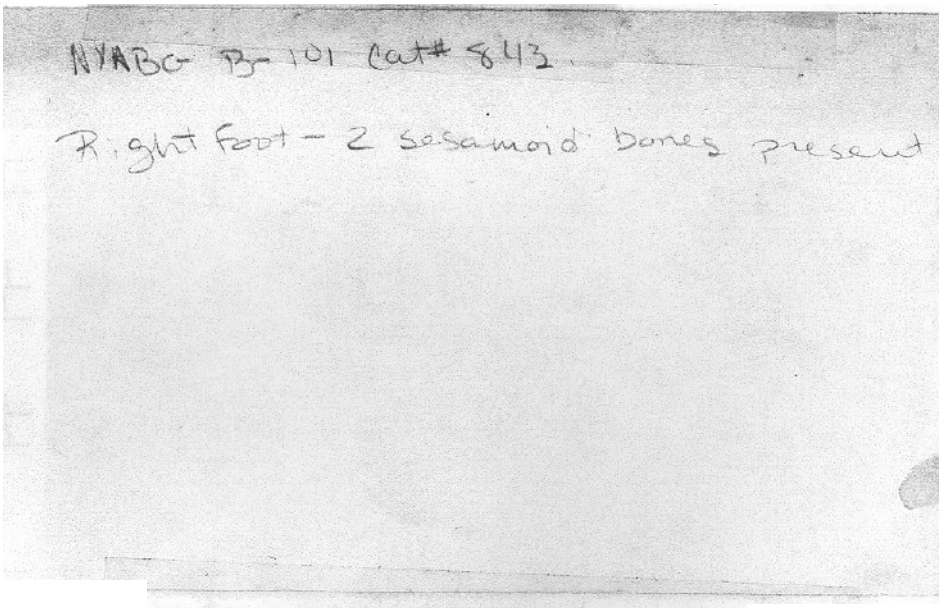
NYABG B-101 Cat# 843.

Right Foot – 2 Sesamoid Bones present

NYABG Burial 101/Cat 843

- Note on 7, 8, 12 thoracic vertebrae.

8 t-vert – superior surface evidence of schmorles Node

7, 8, 12 – t-vert – inferior surface evidence of Schmorles Node Schmorl's

F

ANTHROPOMETRIC RECORD

Burial number : 101.00
Recorder : KS
[illegible] : 35214.00

Cranial Measurements (Pages 53-62)

						LEFT			RIGHT		
Maximum Length (g-op)	189.50	186.00	187.75	[13.] Nasal Height (n-ns)	53.33	53.94	53.64			
Maximum Breadth (eu-eu)	146.50	145.00	145.75	[14.] Nasal Breadth (al-al)	25.11	24.56	24.84			
Bizygomatic Breadth (zy-zy)	133.50	133.00	133.25	[15.] Orbital Breadth (al-al)	43.98	45.26	44.62	43.81	43.71	43.76
Basion-Bregma (ba-b)	136.00	136.00	136.00	[16.] Orbital Height	40.13	40.08	40.11	40.16	41.70	40.93
Cranial Base Length (ba-n)	103.00	102.00	102.50	[17.] Biorbital Br. (ec-ec)	102.76	106.00	104.38			
Basion-Prosthion L. (ba-pr)	110.00	106.00	108.00	[18.] Interorbital Br. (mf-mf)	23.20	22.99	23.10			
Max-Alveolar br. (ecm-ecm)	67.00	69.00	68.00	[19.] Frontal Chord (n-b)	110.86	113.00	111.93			
Max-Alveolar l. (pr-alv)	64.00	63.00	63.50	[20.] Parietal Chord (b-l)	123.27	124.00	123.64			
Biauricular Breadth	120.30	119.00	119.65	[21.] Occipital Chord (l-o)	102.62	102.00	102.31			
Upper Facial Hgt. (n-pr)	70.72	69.72	70.22	[22.] Foramen Magnum (ba-o)	35.61	35.05	35.33			
Min. Frontal Br. (ft-ft)	103.64	103.00	103.32	[23.] Foramen Magnum br	30.76	30.96	30.86			
Upper Facial Br. (fmt-fmt)	109.73	111.29	110.51	[24.] Mastoid Length	33.26	33.19	33.23	32.66	32.77	32.72

MANDIBULAR MEASUREMENTS (Pages 62-65)

			LEFT			RIGHT						
Chin Height (gn-id)			32.83	31.34	32.09		[30.] Min Ramus Breadth	34.27	35.05	34.66	34.28	34.97	34.63
Body Height at Mental for	30.11	30.31	30.21	28.01	28.51	28.26	[31.] Max Ramus Breadth	42.35	42.35	42.35	0.00	0.00	0.00
Body thickness at M. For	11.98	11.70	11.84	12.15	12.43	12.29	[32.] Max Ramus Height	58.82	57.15	57.99	61.46	60.52	60.99
Bigonial Diameter (go-go)			100.90	102.00	101.45		[33] Mand. Length			90.96	90.18	90.57	
Bicondylar Br. (cdl-cdl)			119.76	121.00	120.38		[34.] Mand. Angle			125.00	124.50	124.75	

POSTCRANIAL MEASUREMENTS (Pgs 62-65)

[illegible]VICLE: Epiph. P/A:			LEFT			RIGHT	INNOMINATE: Epiph. P /A			LEFT			RIGHT
[illegible]um Lenght:	150.00	152.00	151.00	150.00	150.00	150.00	[56.] Height:	0.00	0.00	0.00	219.00	219.90	219.45
Sagittal Diam. at Midsh:	14.80	15.08	14.94	14.97	14.22	14.60	[57.] Iliac Breadth:	161.00	162.00	161.50	152.80	152.80	152.80
Vertical Diam. at Midsh:	11.88	12.13	12.01	11.58	11.81	11.70	[58.] Pubis Length:	0.00	0.00	0.00	76.64	75.31	75.98
							[59.] Ischium Length :	0.00	0.00	0.00	83.40	83.50	83.45
SCAPULA: Epiph. P/A:			LEFT			RIGHT	FEMUR: Epiph. P/A:			LEFT			
Anatomical Breadth (HGT) :	166.00	166.00	166.00	0.00	0.00	0.00	[60.] Maximum Length:	501.00	501.50	501.25	495.00	495.50	495.25
Anatomical Length (BR) :	110.00	107.00	108.50	112.00	110.00	111.00	[61.] Bicondylar Length	500.00	500.50	500.25	494.00	495.00	494.50
Glenoid Cav. Lenght:	44.60	46.00	45.30	41.22	42.00	41.61	[62.] Epicondylar Length:	83.00	84.50	83.75	85.00	84.50	84.75
							[63.] Max. Diam. of Head:	49.47	49.50	49.49	49.78	50.00	49.89
HUMERUS: Epiph. P/A:			LEFT			RIGHT	[64.] A/P Subtroch. Diameter:	31.19	31.00	31.10	27.36	28.50	27.93
Maximum Length:	365.00	366.00	365.50	372.00	373.00	372.50	[65.] Transv. Subtroch. Diam:	35.73	36.27	36.00	38.02	38.50	38.26
Epicondylar Breadth:	67.50	70.00	68.75	68.00	69.00	68.50	[66.] Sagittal Diam. Midsh:	31.53	30.07	30.80	30.34	29.00	29.67
Max. Vert. Diam.of Head:	47.35	47.29	47.32	47.28	46.62	46.95	[67.] Tranvs. Diam. Midsh:	29.64	30.50	30.07	30.19	31.00	30.60
Max. Diam. at Midshaft:	23.35	23.20	23.28	23.93	23.47	23.70	[68.] Circumference at Midsh:	95.50	95.50	95.50	95.00	95.50	95.25
Min. Diam. at Midshaft:	19.83	20.64	20.24	19.89	20.73	20.31							
RADIUS: Epiph. P/A:			LEFT			RIGHT	TIBIA: Epiph. P/A:			LEFT			RIGHT
Maximum Lenght:	270.00	269.00	269.50	277.00	278.00	277.50	[69.] Condylo-Malleolar Length:	434.00	436.00	435.00	432.00	431.00	431.50
Sagittal Diam. at Midsh:	13.66	13.95	13.81	13.37	13.55	13.46	[70.] Max. Prox. Epiph. BR:	77.00	80.00	78.50	76.00	77.00	76.50
Transv. Diam. at Midsh	17.38	18.00	17.69	18.52	18.70	18.61	[71.] Max. Dist. Epiph BR:	56.00	55.00	55.50	53.50	52.47	52.99
							[72.] Max. Diam.Nutrient For:	40.96	41.10	41.03	42.48	42.17	42.33
ULNA: Epiph. P/A:			LEFT			RIGHT	[73.] Transv. Diam. Nutr. For:	27.04	26.53	26.79	27.57	26.49	27.03
Maximum Length	294.00	294.00	294.00	302.50	302.00	302.25	[74.] Circum. At Nutr. For:	110.00	108.00	109.00	115.00	114.00	114.50
Dorso-Volar Diameter	12.61	12.33	12.47	13.86	14.30	14.08							
Transverse Diameter	20.40	20.81	20.61	20.29	19.45	19.87	FIBULA: Epiph. P/A:			LEFT			RIGHT
Physiological Length:	248.00	250.00	249.00	257.00	255.00	256.00	[75.] Maximum Length	0.00	0.00	0.00	419.00	420.00	419.50
[illegible]. Circumference:	42.00	42.00	42.00	46.00	44.00	45.00	[76.] Max. Diam. at Midshaft	18.19	18.19	18.19	20.09	20.04	20.07
[illegible]UM: No. Segments:							CALCANEUS: Epiph. P/A:			LEFT			RIGHT
Anterior Length	0.00	0.00	0.00				[77.] Maximum Length:	77.00	77.50	77.25	82.00	80.21	82.00
Anterior-Surface BR:	0.00	0.00	0.00				[78.] Middle Breadth:	44.73	46.18	45.46	46.99	46.32	46.66
Max. Breadth (S-1)	0.00	0.00	0.00										

ANTHROPOMETRIC RECORD

Burial number : 101
Recorder : KS
DATE : 5/29/96

Cranial Measurements (Pages 53-62)

				LEFT					RIGHT	
1 Maximum Length (g-op)	189.50	186	187.8	[13.] Nasal Height (n-ns)	53.33	53.94	53.64			
2 Maximum Breadth (eu-eu)	146.50	145	145.8	[14.] Nasal Breadth (al-al)	25.11	24.56	24.84			
3 Bizygomatic Breadth (zy-zy)	133.50	133	133.3	[15.] Orbital Breadth (al-al)	43.98	45.26	44.62	43.81	43.71	43.8
4 Basion-Bregma (ba-b)	136.00	136	136	[16.] Orbital Height	40.13	40.08	40.11	40.16	41.7	40.9
5 Cranial Base Length (ba-n)	103.00	102	102.5	[17.] Biorbital Br. (ec-ec)	102.76	106	104.4			
6 Basion-Prosthion L. (ba-pr)	110.00	106	108	[18.] Interorbital Br. (mf-mf)	23.2	22.99	23.1			
7 Max-Alveolar br. (ecm-ecm)	67.00	69	68	[19.] Frontal Chord (n-b)	110.86	113	111.9			
8 Max-Alveolar l. (pr-alv)	64.00	63	63.5	[20.] Parietal Chord (b-l)	123.27	124	123.6			
9 Biauricular Breadth	120.30	119	119.7	[21.] Occipital Chord (l-o)	102.62	102	102.3			
10 Upper Facial Hgt. (n-pr)	70.72	69.72	70.22	[22.] Foramen Magnum (ba-o)	35.61	35.05	35.33			
11 Min. Frontal Br. (ft-ft)	103.64	103	103.3	[23.] Foramen Magnum br	30.76	30.96	30.86			
12 Upper Facial Br. (fmt-fmt)	109.73	111.29	110.5	[24.] Mastoid Length	33.26	33.19	33.23	32.66	32.77	32.7

MANDIBULAR MEASUREMENTS (Pages 62-65)

		LEFT			RIGHT			LEFT			RIGHT
25 Chin Height (gn-id)			32.83	31.34	32.1		[30.] Min Ramus Breadth	34.27	35.05	34.66	34.28	34.97	34.6
26 Body Height at Mental for	30.11	30.31	30.21	28.01	28.51	28.26	[31.] Max Ramus Breadth	42.35	42.35	42.35	0	0	0
27 Body thickness at M. For	11.98	11.7	11.84	12.15	12.43	12.29	[32.] Max Ramus Height	58.82	57.15	57.99	61.46	60.52	61
28 Bigonial Diameter (go-go)			100.9	102	101		[33] Mand. Length			90.96	90.18	90.6	
29 Bicondylar Br. (cdl-cdl)			119.76	121	120		[34.] Mand. Angle			125	124.5	125	

POSTCRANIAL MEASUREMENTS (Pgs 62-65)

CLAVICLE: Epiph. P/A:		LEFT			RIGHT		INNOMINATE: Epiph. P /A		LEFT			RIGHT	
Maximum Lenght:	150.00	152	151	150	150	150	[56.] Height:	0	0	0	219	219.9	
36 Sagittal Diam. at Midsh:	14.80	15.08	14.94	14.97	14.22	14.595	[57.] Iliac Breadth:	161	162	161.5	152.8	152.8	
37 Vertical Diam. at Midsh:	11.88	12.13	12.01	11.58	11.81	11.70	[58.] Pubis Length:	0	0	0	76.64	75.31	
							[59.] Ischium Length :	0	0	0	83.4	83.5	8
SCAPULA: Epiph. P/A:		LEFT			RIGHT		FEMUR: Epiph. P/A:		LEFT				
38 Anatomical Breadth (HGT) :	166.00	166	166	0	0	0	[60.] Maximum Length:	501	501.5	501.3	495	495.5	49
39 Anatomical Length (BR) :	110.00	107	108.5	112	110	111	[61.] Bicondylar Length	500	500.5	500.3	494	495	49
Glenoid Cav. Lenght:	44.60	46	45.3	41.22	42	41.61	[62.] Epicondylar Length:	83	84.5	83.75	85	84.5	84.
							[63.] Max. Diam. of Head:	49.47	49.5	49.49	49.78	50	49.9
HUMERUS: Epiph. P/A:		LEFT			RIGHT		[64.] A/P Subtroch. Diameter:	31.19	31	31.1	27.36	28.5	27.9
40 Maximum Length:	365.00	366	365.5	372	373	372.5	[65.] Transv. Subtroch. Diam:	35.73	36.27	36	38.02	38.5	38.3
41 Epicondylar Breadth:	67.50	70	68.75	68	69	68.5	[66.] Sagittal Diam. Midsh:	31.53	30.07	30.8	30.34	29	29.7
42 Max. Vert. Diam.of Head:	47.35	47.29	47.32	47.28	46.62	46.95	[67.] Tranvs. Diam. Midsh:	29.64	30.5	30.07	30.19	31	30.6
43 Max. Diam. at Midshaft:	23.35	23.2	23.28	23.93	23.47	23.7	[68.] Circumference at Midsh:	95.5	95.5	95.5	95	95.5	95.3
44 Min. Diam. at Midshaft:	19.83	20.64	20.24	19.89	20.73	20.31							
RADIUS: Epiph. P/A:		LEFT			RIGHT		TIBIA: Epiph. P/A:		LEFT			RIGHT	
45 Maximum Lenght:	270.00	269	269.5	277	278	277.5	[69.] Condylo-Malleolar Length:	434	436	435	432	431	432
46 Sagittal Diam. at Midsh:	13.66	13.95	13.81	13.37	13.55	13.46	[70.] Max. Prox. Epiph. BR:	77	80	78.5	76	77	76.5
47 Transv. Diam. at Midsh	17.38	18	17.69	18.52	18.7	18.61	[71.] Max. Dist. Epiph BR:	56	55	55.5	53.5	52.47	53
							[72.] Max. Diam.Nutrient For:	40.96	41.1	41.03	42.48	42.17	42.3
ULNA: Epiph. P/A:		LEFT			RIGHT		[73.] Transv. Diam. Nutr. For:	27.04	26.53	26.79	27.57	26.49	27
48 Maximum Length	294.00	294	294	302.5	302	302.25	[74.] Circum. At Nutr. For:	110	108	109	115	114	115
49 Dorso-Volar Diameter	12.61	12.33	12.47	13.86	14.3	14.08							
50 Transverse Diameter	20.40	20.81	20.61	20.29	19.45	19.87	FIBULA: Epiph. P/A:		LEFT			RIGHT	
51 Physiological Length:	248.00	250	249	257	255	256	[75.] Maximum Length	0	0	0	419	42	212
Min. Circumference:	42.00	42	42	46	44	45	[76.] Max. Diam. at Midshaft	18.19	18.19	18.19	20.09	20.04	20.1
SACRUM: No. Segments:							CALCANEUS: Epiph. P/A:		LEFT			RIGHT	
53 Anterior Length	0.00	0	0				[77.] Maximum Length:	77	77.5	77.25	82	80.21	82
54 Anterior-Surface BR:	0.00	0	0				[78.] Middle Breadth:	44.73	46.18	45.46	46.99	46.32	46.7
55 Max. Breadth (S-1)	0.00	0	0										

ANTHROPOMETRIC RECORD

BURIAL NUMBER NYABG B#101 CAT#843
RECORDER: Kaya Shujaa DATE: May 29, 1996

CRANIAL MEASUREMENTS (Pages 53-62)

		Left	Right
1. MAXIMUM LENGTH (g-op):	189.5		
2. MAXIMUM BREADTH (eu-eu):	146.5		
3. BIZYGOMATIC BREADTH (zy-zy):	133.5		
4. BASION-BREGMA (ba-b):	136.0		
5. CRANIAL BASE LENGTH (ba-n):	103.0		
6. BASION-PROSTHION L. (ba-pr):	110.0		
7. MAX.-ALVEOLAR BR. (ecm-ecm):	67.0		
8. MAX.-ALVEOLAR L. (pr-a·v):	64.0		
9. BIAURICULAR BREADTH:	120.30		
10. UPPER FACIAL HGT. (n-pr):	70.72		
11. MIN. FRONTAL BR. (ft-ft):	103.64		
12. UPPER FACIAL BR. (fmt-fmt):	109.43		
13. NASAL HEIGHT (n-ns):		52.33	
14. NASAL BREADTH (al-al):		25.11	
15. ORBITAL BREADTH (mf-ec):		43.98	43.51
16. ORBITAL HEIGHT:		40.13	40.16
17. BIORBITAL BR. (ec-ec):		102.76	
18. INTERORBITAL BR. (mf-mf):		23.20	
19. FRONTAL CHORD (n-b):		110.86	
20. PARIETAL CHORD (b-l):		123.27	
21. OCCIPITAL CHORD (l-o):		102.62	
22. FORAMEN MAGNUM L. (ba-o):		35.61	
23. FORAMEN MAGNUM BR:		30.76	
24. MASTOID LENGTH:		32.26	32.66

MANDIBULAR MEASUREMENTS (Pages 62-65)

	Left	Right		Left	Right
25. CHIN HEIGHT (gn-id):	32.83		30. MIN. RAMUS BREADTH:	34.27	34.28
26. BODY HEIGHT at MENTAL FOR:	30.11	28.01	31. MAX. RAMUS BREADTH:	—	—
27. BODY THICKNESS at M. FOR:	11.98	12.15	32. MAX. RAMUS HEIGHT:	58.82	61.46
28. BIGONIAL DIAMETER (go-go):	100.90		33. MAND. LENGTH:	90.96	
29. BICONDYLAR BR. (cdl-cdl):	~119.76		34. MAND. ANGLE:	125°	

POSTCRANIAL MEASUREMENTS (Pages 65-79)

CLAVICLE: Epiph. P/A:	Left	Right
35. MAXIMUM LENGTH:	150.0	150.0
36. SAGITTAL DIAM. at MIDSH:	14.80	14.97
37. VERTICAL DIAM. at MIDSH:	11.83	11.58

SCAPULA: Epiph. P/A:	Left	Right
38. ANATOMICAL BREADTH (HGT):	166.0	—
39. ANATOMICAL LENGTH (BR):	110.0	112.0
GLENOID CAV. LENGTH:	41.60	41.22

HUMERUS: Epiph. P/A:	Left	Right
* 40. MAXIMUM LENGTH:	365.0	323.0
41. EPICONDYLAR BREADTH:	67.5	68.0
42. MAX. VERT. DIAM. of HEAD:	43.35	47.28
43. MAX. DIAM. at MIDSHAFT:	23.35	23.93
44. MIN. DIAM. at MIDSHAFT:	19.33	19.89
Antic. width	43.67	44.33

RADIUS: Epiph. P/A:	Left	Right
* 45. MAXIMUM LENGTH:	270.0	277.0
46. SAGITTAL DIAM. at MIDSH:	13.66	13.37
47. TRANSV. DIAM. at MIDSH:	~ 17.37	18.52

ULNA: Epiph. P/A:	Left	Right
* 48. MAXIMUM LENGTH:	294.0	302.5
49. DORSO-VOLAR DIAMETER:	12.61	13.76
50. TRANSVERSE DIAMETER:	20.40	20.29
51. PHYSIOLOGICAL LENGTH:	248.0	257.0
52. MIN. CIRCUMFERENCE:	43.10	46.0

SACRUM: No. Segments:		
53. ANTERIOR LENGTH:	—	
54. ANTERIOR-SURFACE BR:	—	
55. MAX. BREADTH (S-1)	—	

INNOMINATE: Epiph. P/A:	Left	Right
56. HEIGHT:	—	219.0
57. ILIAC BREADTH:	116.0	—
58. PUBIS LENGTH:	—	76.64
59. ISCHIUM LENGTH:	—	83.40

FEMUR: Epiph. P/A:	Left	Right
60. MAXIMUM LENGTH:	501.0	495.0
61. BICONDYLAR LENGTH:	500	494.0
62. EPICONDYLAR BREADTH:	88.0	85.0
63. MAX. DIAM. of HEAD:	49.47	49.28
64. A/P SUBTROCH. DIAMETER:	31.19	29.36
65. TRANSV. SUBTROCH. DIAM:	35.73	38.02
66. SAGITTAL DIAM. MIDSH:	~31.53	~30.34
67. TRANVS. DIAM. MIDSH:	29.64	30.19
68. CIRCUMFERENCE AT MIDSH:	95.5	95.0

TIBIA: Epiph. P/A:	Left	Right
69. CONDYLO-MALLEOLAR LENGTH:	428.0	432.0
70. MAX. PROX. EPIPH. BR:	77.0	76.0
71. MAX. DIST. EPIPH. BR:	56.0	53.5
72. MAX. DIAM. NUTRIENT FOR:	40.96	42.48
73. TRANSV. DIAM. NUTR. FOR:	27.04	27.57
74. CIRCUM. AT NUTR. FOR:	110.0	113.0

FIBULA: Epiph. P/A:	Left	Right
75. MAXIMUM LENGTH:	—	419.0
76. MAX. DIAM. at MIDSHAFT:	—	20.09

CALCANEUS: Epiph. P/A:	Left	Right
77. MAXIMUM LENGTH:	77.5	82.0
78. MIDDLE BREADTH:	44.73	46.99

* 40 R. Humerus is visibly longer than the left. Both are in very good condition.
* 45 & 48 – R. Radius & R. Ulna are visibly longer than counterparts

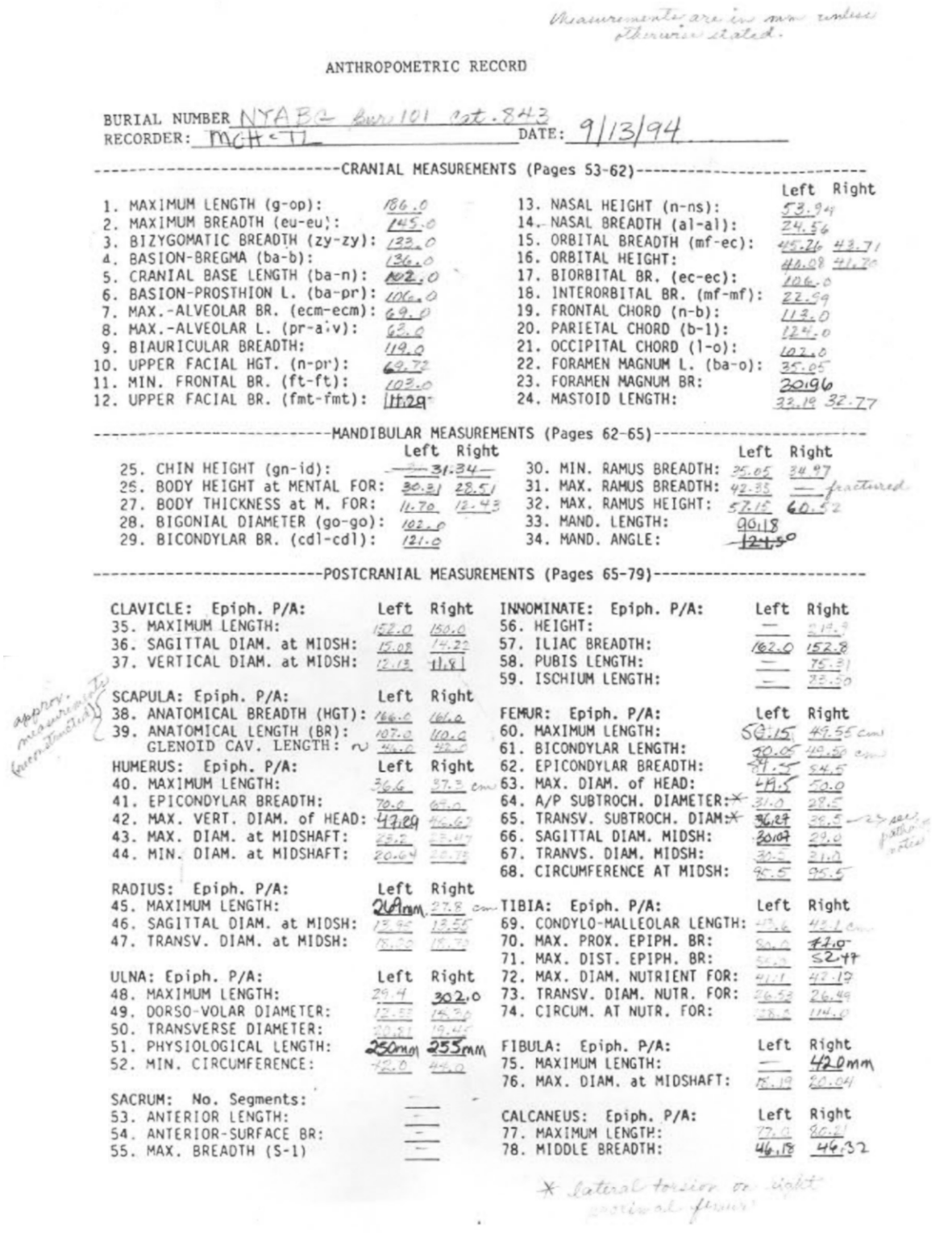

Measurements are in mm unless otherwise stated.

ANTHROPOMETRIC RECORD

BURIAL NUMBER NYABG Burial 101 Cat. 843
RECORDER: MCH-TL DATE: 9/13/94

CRANIAL MEASUREMENTS (Pages 53-62)

		Left	Right
1. MAXIMUM LENGTH (g-op):	186.0	13. NASAL HEIGHT (n-ns):	53.94	
2. MAXIMUM BREADTH (eu-eu):	145.0	14. NASAL BREADTH (al-al):	24.56	
3. BIZYGOMATIC BREADTH (zy-zy):	133.0	15. ORBITAL BREADTH (mf-ec):	45.26	43.71
4. BASION-BREGMA (ba-b):	136.0	16. ORBITAL HEIGHT:	44.08	41.20
5. CRANIAL BASE LENGTH (ba-n):	102.0	17. BIORBITAL BR. (ec-ec):	106.0	
6. BASION-PROSTHION L. (ba-pr):	106.0	18. INTERORBITAL BR. (mf-mf):	22.59	
7. MAX.-ALVEOLAR BR. (ecm-ecm):	69.0	19. FRONTAL CHORD (n-b):	113.0	
8. MAX.-ALVEOLAR L. (pr-a:v):	62.0	20. PARIETAL CHORD (b-l):	124.0	
9. BIAURICULAR BREADTH:	119.0	21. OCCIPITAL CHORD (l-o):	102.0	
10. UPPER FACIAL HGT. (n-pr):	69.72	22. FORAMEN MAGNUM L. (ba-o):	35.05	
11. MIN. FRONTAL BR. (ft-ft):	103.0	23. FORAMEN MAGNUM BR:	20.96	
12. UPPER FACIAL BR. (fmt-fmt):	11.29	24. MASTOID LENGTH:	33.19	32.77

MANDIBULAR MEASUREMENTS (Pages 62-65)

	Left	Right		Left	Right
25. CHIN HEIGHT (gn-id):		31.34	30. MIN. RAMUS BREADTH:	35.05	34.97
26. BODY HEIGHT at MENTAL FOR:	30.31	28.51	31. MAX. RAMUS BREADTH:	42.33	— fractured
27. BODY THICKNESS at M. FOR:	11.70	12.43	32. MAX. RAMUS HEIGHT:	57.15	60.52
28. BIGONIAL DIAMETER (go-go):	102.0		33. MAND. LENGTH:	90.18	
29. BICONDYLAR BR. (cdl-cdl):	121.0		34. MAND. ANGLE:	~~124.50~~	

POSTCRANIAL MEASUREMENTS (Pages 65-79)

CLAVICLE: Epiph. P/A:	Left	Right
35. MAXIMUM LENGTH:	152.0	150.0
36. SAGITTAL DIAM. at MIDSH:	15.08	14.22
37. VERTICAL DIAM. at MIDSH:	12.13	11.81

SCAPULA: Epiph. P/A:	Left	Right
38. ANATOMICAL BREADTH (HGT):	166.0	166.0
39. ANATOMICAL LENGTH (BR):	107.0	110.0
GLENOID CAV. LENGTH: ~	40.0	42.0

approx. measurements (mm estimated)

HUMERUS: Epiph. P/A:	Left	Right
40. MAXIMUM LENGTH:	326.6	327.3 cm
41. EPICONDYLAR BREADTH:	70.0	69.0
42. MAX. VERT. DIAM. of HEAD:	47.89	46.62
43. MAX. DIAM. at MIDSHAFT:	25.7	25.47
44. MIN. DIAM. at MIDSHAFT:	20.64	20.18

RADIUS: Epiph. P/A:	Left	Right
45. MAXIMUM LENGTH:	249mm	247.8 cm
46. SAGITTAL DIAM. at MIDSH:	13.62	13.56
47. TRANSV. DIAM. at MIDSH:	16.23	16.73

ULNA: Epiph. P/A:	Left	Right
48. MAXIMUM LENGTH:	29.4	302.0
49. DORSO-VOLAR DIAMETER:	12.55	14.59
50. TRANSVERSE DIAMETER:	20.91	19.45
51. PHYSIOLOGICAL LENGTH:	250mm	253mm
52. MIN. CIRCUMFERENCE:	42.0	44.0

SACRUM: No. Segments:	
53. ANTERIOR LENGTH:	—
54. ANTERIOR-SURFACE BR:	—
55. MAX. BREADTH (S-1)	—

INNOMINATE: Epiph. P/A:	Left	Right
56. HEIGHT:	—	219.9
57. ILIAC BREADTH:	162.0	152.8
58. PUBIS LENGTH:	—	75.31
59. ISCHIUM LENGTH:	—	73.50

FEMUR: Epiph. P/A:	Left	Right
60. MAXIMUM LENGTH:	502.15	49.55 cm
61. BICONDYLAR LENGTH:	490.05	489.50 cm
62. EPICONDYLAR BREADTH:	89.25	84.5
63. MAX. DIAM. of HEAD:	49.5	50.0
64. A/P SUBTROCH. DIAMETER:*	31.0	28.5
65. TRANSV. SUBTROCH. DIAM:*	36.27	29.5 — 27 per pathology notes
66. SAGITTAL DIAM. MIDSH:	30.07	29.0
67. TRANVS. DIAM. MIDSH:	30.5	21.0
68. CIRCUMFERENCE AT MIDSH:	95.5	95.5

TIBIA: Epiph. P/A:	Left	Right
69. CONDYLO-MALLEOLAR LENGTH:	419.6	412.1 cm
70. MAX. PROX. EPIPH. BR:	90.0	87.0
71. MAX. DIST. EPIPH. BR:	52.0	52.47
72. MAX. DIAM. NUTRIENT FOR:	41.11	42.19
73. TRANSV. DIAM. NUTR. FOR:	26.52	26.49
74. CIRCUM. AT NUTR. FOR:	118.8	114.0

FIBULA: Epiph. P/A:	Left	Right
75. MAXIMUM LENGTH:	—	420mm
76. MAX. DIAM. at MIDSHAFT:	18.19	20.04

CALCANEUS: Epiph. P/A:	Left	Right
77. MAXIMUM LENGTH:	77.0	80.61
78. MIDDLE BREADTH:	46.18	46.32

* Lateral torsion of right proximal femur

BURIAL No: 101
RECORDER :
DATE :

IMMATURE MEASUREMENTS

	LEFT						RIGHT		
1. Lesser wing of sphenoid									
a. Length				0.00	0.00	0.00			
b. Width				0.00	0.00	0.00			
2. Greater wing of sphenoid									
a. Length	0.00	0.00	0.00				0.00	0.00	0.00
b. Width	0.00	0.00	0.00				0.00	0.00	0.00
3. Body of sphenoid									
a. Length				0.00	0.00	0.00			
b. Width				0.00	0.00	0.00			
4. Petrous-mastoid of temporal									
a. Length	0.00	0.00	0.00				0.00	0.00	0.00
b. Width	0.00	0.00	0.00				0.00	0.00	0.00
5. Basilar occipital									
a. Length				0.00	0.00	0.00			
b. Width				0.00	0.00	0.00			
6. Zygomatic									
a. Length	0.00	0.00	0.00				0.00	0.00	0.00
b. Width	0.00	0.00	0.00				0.00	0.00	0.00
7. Maxilla									
a. Length	0.00	0.00	0.00				0.00	0.00	0.00
b. Height	0.00	0.00	0.00				0.00	0.00	0.00
c. Width	0.00	0.00	0.00				0.00	0.00	0.00
d. Oblique length	0.00	0.00	0.00				0.00	0.00	0.00
8. Mandible									
a. Length	0.00	0.00	0.00				0.00	0.00	0.00
b. Width	0.00	0.00	0.00				0.00	0.00	0.00
c. Full length	0.00	0.00	0.00				0.00	0.00	0.00
9. Clavicle									
a. Length	0.00	0.00	0.00				0.00	0.00	0.00
b. Diameter	0.00	0.00	0.00				0.00	0.00	0.00
10. Scapula									
a. Length	0.00	0.00	0.00				0.00	0.00	0.00
b. Width	0.00	0.00	0.00				0.00	0.00	0.00
c. Length of spine	0.00	0.00	0.00				0.00	0.00	0.00
11. ilium									
a. Length	0.00	0.00	0.00				0.00	0.00	0.00
b. Width	0.00	0.00	0.00				0.00	0.00	0.00
12. Ischium									
a. Length	0.00	0.00	0.00				0.00	0.00	0.00
b. Width	0.00	0.00	0.00				0.00	0.00	0.00

IMMATURE MEASUREMENTS

	LEFT			RIGHT		
13. Pubis						
a. Length	0.00	0.00	**0.00**	0.00	0.00	**0.00**
14. Humerus						
a. Length	0.00	0.00	**0.00**	0.00	0.00	**0.00**
b. Width	0.00	0.00	**0.00**	0.00	0.00	**0.00**
c. Diameter	0.00	0.00	**0.00**	0.00	0.00	**0.00**
15. Ulna						
a. Length	0.00	0.00	**0.00**	0.00	0.00	**0.00**
b. Diameter	0.00	0.00	**0.00**	0.00	0.00	**0.00**
16. Radius						
a. Length	0.00	0.00	**0.00**	0.00	0.00	**0.00**
b. Diameter	0.00	0.00	**0.00**	0.00	0.00	**0.00**
17. Femur						
a. Length	0.00	0.00	**0.00**	0.00	0.00	**0.00**
b. Width	0.00	0.00	**0.00**	0.00	0.00	**0.00**
c. Diameter	0.00	0.00	**0.00**	0.00	0.00	**0.00**
18. Tibia						
a. Length	0.00	0.00	**0.00**	0.00	0.00	**0.00**
b. Diameter	0.00	0.00	**0.00**	0.00	0.00	**0.00**
19. Fibula						
a. Length	0.00	0.00	**0.00**	0.00	0.00	**0.00**
b. Diameter	0.00	0.00	**0.00**	0.00	0.00	**0.00**

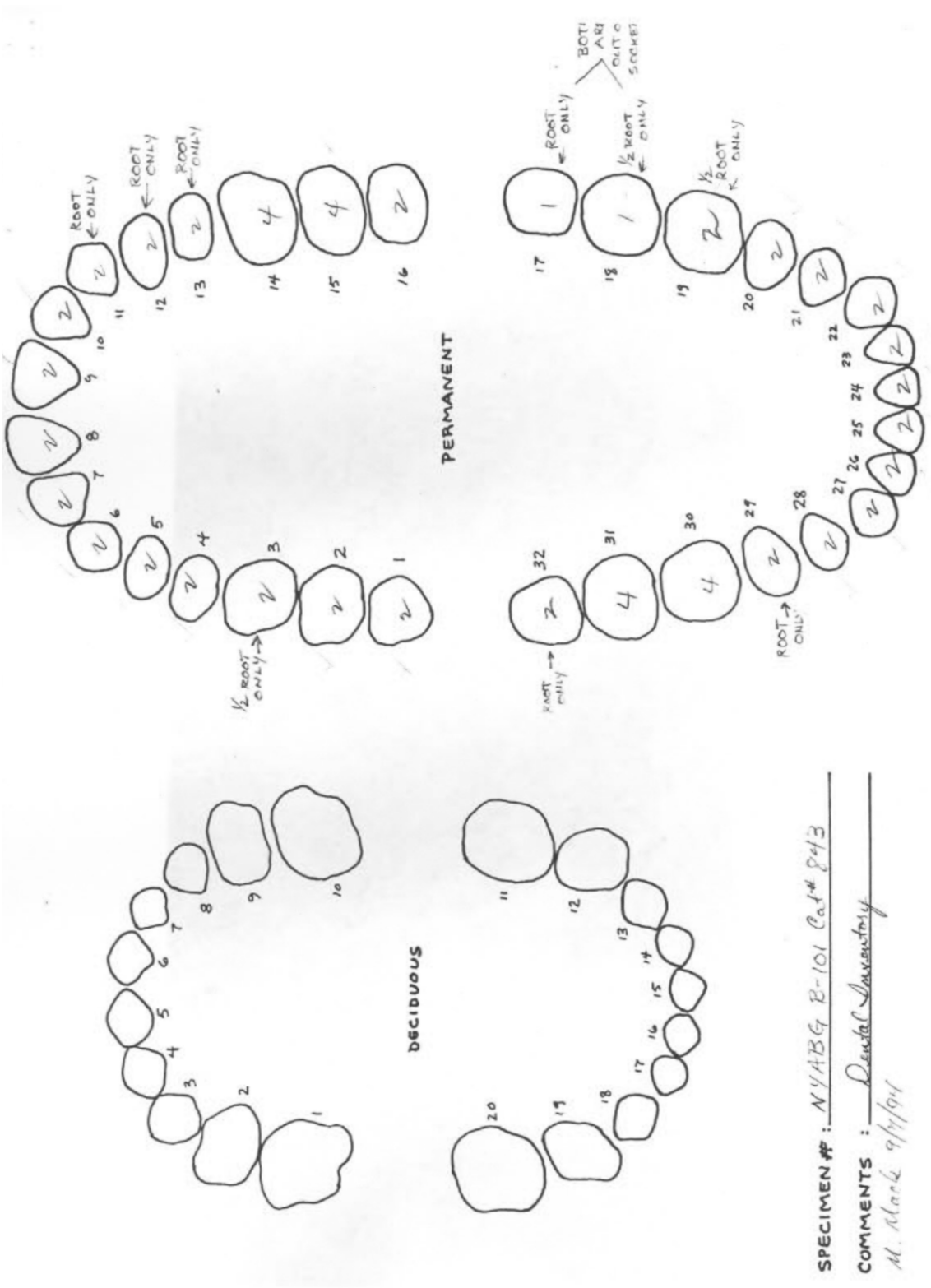
PERMANENT
DECIDUOUS
SPECIMEN #: NYABG B-101 Cat# 843
COMMENTS: Dental Anomaly
M. Mack 9/7/01

DENTAL MEASUREMENT FORM

Site Name/Number NYABG 1
Feature/Burial Number B-101 1
Burial/Skeleton Number Cat# 9431

Observer M. Mack
Date 9/17/94

TOOTH		MEASUREMENTS			TOOTH		MEASUREMENTS		
LEFT MAX.		MD	BL	CH	RIGHT MAX.		MD	BL	CH
9	^1I	(18)	7.62	11.97	1	M^3	(18)	(18)	(18)
10	^2I	6.54	6.76	10.18	2	M^2	11.70	12.26	7.84
11	^xC	(18)	(18)	(18)	3	M^1	(18)	(18)	(18)
12	^1P	(18)	(18)	(18)	4	P^2	7.79	10.08	8.69
13	^2P	(18)	(18)	(18)	5	P^1	7.81	10.21	8.97
14	^1M	(18)	(18)	(18)	6	C^x	8.11	9.46	11.04
15	^2M	(18)	(18)	(18)	7	I^2	6.46	6.95	9.94
16	^3M	10.27	12.19	7.41	8	I^1	*	7.59	11.50
LEFT MAND.		MD	BL	CH	RIGHT MAND.		MD	BL	CH
17	$_3M$	(15)	(15)	(15)	25	I_1	5.78	6.09	9.35
18	$_2M$	(18)	(18)	(18)	26	I_2	5.99	6.61	9.86
19	$_1M$	(18)	(18)	(18)	27	C_x	7.65	8.32	11.20
20	$_2P$	7.87	9.69	8.25	28	P_1	7.75	9.12	8.95
21	$_1P$	7.83	9.40	8.96	29	P_2	(18)	(18)	(18)
22	$_xC$	7.72	8.13	11.21	30	M_1	(15)	(15)	(15)
23	$_2I$	6.54	6.74	9.73	31	M_2	(15)	(15)	(15)
24	$_1I$	5.52	6.07	9.05	32	M_3	(18)	(18)	(18)

* = caries damage prevents observation (18)
- = ~~tooth~~ is absent (15)

Site Name: NYABG
Burial #: B-101
Catalog #: 843

Observer: M Mack
Date: 1/5/96

DENTAL MORPHOLOGY

WINGING	¹I¹ 3						* = caries damage prevents (18) observation
SHOVELING	²I 1	¹I 0	I¹ 0	I² 1			– = tooth is absent (15)
CURVATURE OF LABIAL SURFACE	²I 0	¹I 0	I¹ 0	I² 0			// = root in alveolus, prevents observation (21)
DOUBLE SHOVELING	²I 0	¹I 0	I¹ 0	I¹ 0			
INTERRUPTION GROOVE	²I 0	I² 0					
TUBERCULUM DENTALE	²I 0	¹I 0	I¹ 0	I² 0			
CANINE MESIAL RIDGE	²C 18	C¹ 0					
CAN. DIST. ACCESSORY RIDGE	²C 18	C¹ 0	,C 0	C, 0			
PM MES. & DIST. ACCESS. CUSPS	²PM 18	¹PM 18	PM¹ 0	PM² 1			
TRI-CUSPED PREMOLAR	²PM 18	¹PM 18	PM¹ 0	PM² 0			
DISTOSAGITTAL RIDGE	¹PM 18	PM² 0					
METACONE	²M 3	²M 15	¹M 15	M¹ 18	M² 3.5	M³ 18	
HYPOCONE	²M 18	²M 15	¹M 15	M¹ 18	M² 3.5	M³ 18	
METACONULE	²M 18	²M 15	¹M 15	M¹ 18	M² 0	M³ 18	
CARABELLI'S TRAIT	²M 1	²M 15	¹M 15	M¹ 18	M² 1	M³ 1	
PARASTYLE	²M 0	M³ 18					
ENAMEL EXTENSIONS	²M 0	²M 15	¹M 15	²PM 18	¹PM 18		
	PM² 0	PM² 0	M¹ 18	M² 0	M³ 0		
PREMOLAR ROOT NUMBER	²PM 21	¹PM 21	PM 21	PM² 21			
UPPER MOLAR ROOT NUMBER	²M 21	²M 15	¹M 15	M¹ 21	M² 21	M³ 21	
PEG-SHAPED INCISOR	²I 1	I² 1					
PEG-SHAPED MOLAR	²M 0	M³ 0					
ODONTOME	²PM 18	¹PM 18	PM² 0	PM² 0			
	,PM 0	,PM 0	PM, 0	PM, 18			
CONGENITAL ABSENCE	None						
LOWER PM CUSP VARIATION	,PM 9	,PM 0	PM, 0	PM, 18			
ANTERIOR FOVEA	,M 18	M, 15					
GROVE PATTERN	,M 18	,M 18	,M 18	M, 15	M, 15	M, 18	
CUSP NUMBER	,M 18	,M 18	,M 18	M, 15	M, 15	M, 18	
DEFLECTING WRINKLE	,M 18	M, 15					
DISTAL TRIGONID CREST	,M 18	M, 15					
PROTOSTYLID	,M 18	,M 18	,M 18	M, 15	M, 15	M, 18	
CUSP 5	,M 18	,M 18	,M 18	M, 15	M, 15	M, 18	
CUSP 6	,M 18	,M 18	,M 18	M, 15	M, 15	M, 18	
CUSP 7	,M 18	,M 18	,M 18	M, 15	M, 15	M, 18	
CANINE ROOT #	,C 1	C, 1					
ʼDME'S ROOT	,PM 21	PM, 21					
LOWER ROOT #	,M 18	,M 18	M, 15	M, 15			
TORSOMOLAR ANGLE	,M 18	M, 18					

Dental Wear Score

Specimen # NYABG B-101 Cat# 843 Observer & Date M. Mack 1/9/98

Scores of I^1_1 - PM^2_2 described in Smith B. Holly AJPA 63:39-56(1984)

	Maxilla	Mandible
1 LI 1	2	2
1 RI	2	2
2 LI 2	2	2
2 RI	2	2
1 LC 1	8	2
1 RC	2	2
1 LPM 1	8	2
1 RPM	2	2
2 LPM 2	8	2
2 RPM	2	10

Quadrants

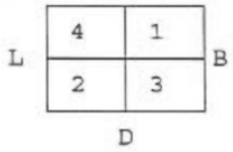

— = tooth is absent

Molar score described in Scott E.C. AJPA 51:213-218(1979)

Quad.	1	2	3	4	Total Score	Quad.	1	2	3	4	Total Score
1 LM 1	—	—	—	—	= —	LM 1	10	10	10	10	= 40
RM	10	10	10	10	= 40	RM 1	—	—	—	—	= —
2 LM 2	—	—	—	—	= —	LM 2	10	10	10	10	= 40
RM	2	2	2	2	= 8	RM 2	—	—	—	—	= —
3 LM 3	1	7	2	1	= 11	LM 3	10	10	10	10	= 40
RM	8	3	10	8	= 29	RM 3	10	10	10	10	= 40



Enamel Defect Measurement

Specimen # NYABG 8-101 Cat# 843 Observer & Date M Mack 1/9/96

Coding for 'X' 165

X = carious damage prevents bilateral observation

Maxilla	Tooth CH	/Def Type	/Inc	/Cor	/Bil	/Age	/	Mandible	Tooth CH	/Def Type	/Inc	/Cor	/Bil	/Age	/
L I 1	11.97	HC	5.86	1.97	y		
		HP	9.41	7.87	y	0.96	1.77
I 1															
L I 2	10.18	HC	8.00	2.07	y		
									9.73	HC	1.88	1.00	y		
R C 1	11.04	HC	6.81	1.65	X		
								L C 1	11.21	HC	3.90	1.58	y		
										HP	7.10	midpoint	y	2.70	
R PM 1	8.97	HC	6.63	4.77	X		
		HC	2.60	0.00	X		
L PM 1	8.96	HC	2.22	0.94	y		
		HP	5.25	midpoint	y	3.07	
R PM 2	8.69	HC	8.69	4.70	X		
		HC	2.73	0.00	X		
L PM 2	8.25	HC	6.20	1.48	X		
		HP	5.30	midpoint	X	3.79	
M 1	Lateral - X						
M 1							
R M 2	7.84	HC	7.84	0.00	X		
M 2							
L M 3	7.41	HC	7.41	1.55	y		
M 3							

New York African Burial
Dental Pathology Notes

Specimen# NYABG B-101 Cat# 843 Observer and Date M. Mack 1/10/96

Caries: (1:61) (2: 21-mesial, 15)(3:61)(4:21-mesial/occlusal)(8+9:2,2 — (1mesial, 1 distal: located at sites of enamel hypoplasia pits - see photo. (11:61), (12:61), (13:61), (16:13), (17:61)(18:61)(19:61)(20:21-mesial) (28:21-mesial)(29:61)(32:61)

Abscessing: (3:2)(12:1)(15:2) (17: possible 2)(18: possible 1)(19: possible 1)(11:1) (31:1) - see photo for all

Severe alveolar recession @ roots for all present dentition - see photo

Enamel Hypoplasia: present on (8:3), (9:3)(20:1)(21:1)(22:1)(27:1)(28:1)

Enamel Hypocalcification: present on (1:6,4), (2:6,4)(4:6,4(2))(5:6,4(2))(6:6,4) (7:6,4)(8:6,4)(9:6,4)(16:6,4)(20:6,4)(21:6,4)(22:6,4)(23:6,4) (26:6,4)(27:6,4)(28:6,4)

* Possible chipping of distal/occlusal edges of LI's & RI' - may be in response to enamel hypoplasia pits @ that location - see photo!

* Marked periostitis along alveolar margins from (RM³, RM², RM', RPM², RPM') and (LC', LPM', LPM², LM', LM², LM³) - see photo

Page 1 of 5

Site Name: NYABG
Burial #: 101
Catalog #: 843

Observer: ADavis
Date: 4/17/96

NEW YORK AFRICAN BURIAL GROUND PROJECT
AGE DETERMINATION FORM

1) **Cranial Suture Closure**

A. **Ectocranial** 0=Open 1=Minimal Closure 2=Significant Closure 3=Complete Obliteration

Site	Score	Site	Score
1) Midlambdoid(V)	1	6) Midcoronal(V/L-A)	1
2) Lambda(V)	0	7) Pterion(V/L-A)	2.5
3) Obelion(V)	0	8) Sphenofrontal(L-A)	2.5
4) Ant. Sagittal(V)	0	9) Inf. Sphenotemporal(L-A)	3
5) Bregma(V)	0	10) Sup. Sphenotemporal(L-A)	2

Age Estimate: Vault 34.7±7.8 Lateral-Anterior 51.9±12.3
Comments: _____

B. **Endocranial** 1=Open 2=Partial Closure 3=Complete Closure NA

Site	Score	Site	Score
1) Sagittal		4) Coronal(L)	
2) Lambdoid(L)		5) Coronal(R)	
3) Lambdoid(R)			

Age Estimate_____ Comments_____

2A. **Dental Development** (Moorees, Fanning, & Hunt 1963a, 1963b) NA

Code	Stage	Code	Stage	Code	Stage
1)	Initial Cusp Form	6)	Crown Complete	11)	Root Length 3/4
2)	Coalescence of Cusps	7)	Initial Root Form.	12)	Root Length Complete
3)	Cusp Outline Comp.	8)	Init. Cleft Form.	13)	Apex 1/2 Closed
4)	Crown 1/2 Comp.	9)	Root Length 1/4	14)	Apical Closure Comp
5)	Crown 3/4 Comp.	10)	Root Length 1/2		

Tooth	rm^2	rm^1	rc^1	ri^2	ri^1	li^1	li^2	lc^1	lm^1	lm^2
Score										

Tooth	rm_2	rm_1	rc_1	ri_2	ri_1	li_1	li_2	lc_1	lm_1	lm_2
Score										

Tooth	RM^3	RM^2	RM^1	RPM^2	RPM^1	RC^1	RI^2	RI^1	LI^1	LC^1	LPM^1
Score											

Tooth	LPM^2	LM^1	LM^2	LM^3
Score				

Site Name: N4ABG
Burial #: 101
Catalog #: 843

Observer: ADavis
Date: 4/17/96

NEW YORK AFRICAN BURIAL GROUND PROJECT
AGE DETERMINATION FORM

Tooth	RM_3	RM_2	RM_1	RPM_2	RPM_1	RC_1	RI_2	RI_1	LI_1	LC_1	LPM_1
Score	___	___	___	___	___	___	___	___	___	___	___

Tooth	LPM_2	LM_1	LM_2	LM_3
Score	___	___	___	___

Summary Age: _____
Comments: _____

2B. Dental Development (Ubelaker, 1989)

Summary Age: +21
Comments: The teeth are generally in good shape, but the molar crowns are eaten away and the roots remain in the crypt. Third molar erupted but cannot tell if molar root completed.

2C. Dental Development (Gustafson & Koch, 1974)

Summary Age: _____
Comments: _____

3. Epiphyseal Union 0 = Unobservable 1 = No Union 2 = Partial 3 = Complete

Epiphysis	Stage	Age (♀)	Age (Both)	Age (♂)	Estimate
Basilsar	3		18.0 - 25.0		+18
Med. Clavicle	2		25.0 - 28.0		25-28
Acromial End			19.0 - 20.0		
Scap-Acrom			18.0 - 19.0		
Vert. Margin			20.0 - 21.0		
Inf. Angle			20.0 - 21.0		
Atlas-Anterior		(6.0)		(6.0)	
Atlas-Posterior		(3.0)		(3.0 - 4.0)	
Axis-Anterior			3.0 - 4.0		
Axis-Posterior			3.0 - 4.0		
Cerv. Vert. Rim	3		17.0 - 25.0		+17
Thor. Vert. Rim	3		17.0 - 25.0		+17
L5 Body/Arch			3.0 - 7.0		
Sacrum (S1/2)	0		20.0 - 33.0+		?
Sacrum (S2/3)			17.0 - 24.0		
Sacrum (S3/4)			17.0 - 23.0		
Ischial Tuber			19.0 - 20.0		
Primary Element			13.0 - 15.0		
Ant. Iliac Crest		(17.0 - 24.0)		(18.0 - 24.0)	
Prox. Humerus		(15.8 - 18.2)		(16.0 - 18.2)	
		(13.4 - 16.4)		(14.0 - 16.4)	

Site Name: NYABG
Burial #: 101
Catalog #: 343

Observer: ADavis
Date: 9/17/96

NEW YORK AFRICAN BURIAL GROUND PROJECT
AGE DETERMINATION FORM

Med. Epic. Hum.		(10.0 - 14.0)	(12.0 - 14.0)	
Prox. Radius		14.6 - 15.8		
Dist. Radius		18.0 - 19.0		
Prox. Ulna		(13.1 - 15.0)	(14.0 - 15.0)	
Dist. Ulna		18.0 - 19.0		
Femur Head		(13.4 - 16.4)	(14.0 - 16.4)	
Gr. Trochanter		17.0 - 18.0		
Ls. Trochanter		17.0 - 18.0		
Dist. Femur		(14.0 - 17.0)	(16.0 - 17.0)	
Prox. Tibia		(14.0 - 18.0)	(15.0 - 18.0)	
Dist. Tibia		(13.0 - 18.0)	(14.9 - 18.0)	
Prox. Fibula		(14.0 - 18.0)	(16.0 - 18.0)	

3. Epiphyseal Union, Continued +25 ≤28

Consensus epiphyseal union: All observable ends are fused
Comments: except the medial clavicle seems to be only partially fused

4. Sternal Rib Change: phase: 4 age: 26-32 [29 years ±3 years]
Comments: The pit is U-shaped - no scalloping. Walls still pretty thick

5. Pubic Symphysis

A. Suchy-Brooks: phase: III-1 age: 28.7 ± 6.5
Comments: Some billowing remains

B. Revised Todd: phase: VI age: 30-35 [32.5 ±2.5]
Comments: Ventral Rampart not complete

6. Auricular Surface: phase: 5 age: 30-34 [32±2]
Comments: Granularity and transverse organization (slight) and small amount of microporosity. Prominent striae

Composite Age: 30 - 35 years [32.5 years ±2.5 years]
Comments: This individual is in his Thirties. Most of the indicators point this way. (Due to the excellent preservation nearly all of the skeleton could be assessed for age.)

Page 4 of 5

Site Name:_____ Observer:_____
Burial #:_____ Date:_____
Catalog #:_____

NEW YORK AFRICAN BURIAL GROUND PROJECT
AGE DETERMINATION FORM

_____

_____

_____

_____

_____

_____

Seriated Age Indicators

1) Dental Attrition(See Dental Wear Form)

Score:_____ Age:___ Seriated Age:___

Comments:_____

_____

2) Osteoarthritic Change

0 = No Lipping 1 = Minimal 2 = Moderate 3 = Significant 4 = Maximum

C1	C2	C3	C4	C5	C6	C7	T1	T2	T3	T4	T5	T6	T7	T8
0	0	1	0	1	0	0	0	1	0	0	0	0	0	0

T9	T10	T11	T12	L1	L2	L3	L4	L5
0	0	0	0	0	0	0	0	0

humeral head 0 prox. tibia 0
dist. humerus 0
femoral head 0
dist. femur 0
Seriated age ___
Comments:_____

_____

Page 5 of 5

Site Name:_____ Observer:_____
Burial #:_____ Date:_____
Catalog #:_____

NEW YORK AFRICAN BURIAL GROUND PROJECT
AGE DETERMINATION FORM

3) Osteonal Remodeling

Seriated age ___
Comments:_____

_____

4) Multifactorial Age

Seriated age ___
Comments:_____

_____

SEX DETERMINATION

SITE NYABG RECORDER ADavis
BURIAL # 101 DATE 4/17/96
CAT# 843

		SCORE				
I)	Cranial	F				M
	1. supraorbital ridge & glabella	1	2	3	(4)	5
	2. zygomatic arch	1	2	3	(4)	5
	*3. mastoid process	1	2	3	4	(5)
	a. mastoid length L_____ R_____	1	2	3	4	5
	4. occipital region	1	2	3	(4)	(5)
	5. gonial region	1	2	3	(4)	5
	6. eye orbit margin	1	2	3	(4)	5
	7. mental eminence	1	2	3	(4)	5
	8. temporal line	1	2	(3)	4	5
	9. palate length _____	1	2	3	4	5
	10. overall robusticity	1	2	3	4	(5)
II)	Postcranial all measurements in millimeters measurements transported from orginal measurement sheet					
	11. humerus	1	2	3	4	5
	a. vertical diam. humeral head L 44.79 R 46.62	1	2	3	(4)	5
	b. transverse diam. humeral head L_____ R_____	1	2	3	4	5
	c. biepicondylar width L 70 R 69	1	2	3	4	(5)
	d. articular width L_____ R_____	1	2	3	4	5
	12. sternal length	1	2	3	4	5
	manubrium_____ mesosternum_____ total =_____					
	13. clavicle (length) L 152 R 150	1	2	3	4	(5)
	14. scapula					
	a. glenoid cavity length L 46 R 42	1	2	3	4	(5)
	15. femur					
	a. max. diam. femoral head L 49.5 R 50	1	2	3	4	(5)
	b. femoral midshaft circumf. L 95.5 R 95.5	1	2	3	4	(5)
	c. linea aspera	1	2	3	(4)	5
	16. tibia	1	2	3	4	(5)
	circumf. @ nutrient foramen L 108 R 114	1	2	3	4	(5)
	*17. overall robusticity	1	2	3	4	(5)

NYABG B·101
Cat 843

SEX DETERMINATION

III) Pelvis

		F			M
*18.	os pubis	1	2	3	4 (5)
	a. ventral arc	NONE			
	b. subpubic concavity	NARROW			
	c. medial ridge	FLAT			
19.	pre-auricular sulcus	1	2	3	4 (5)
*20.	greater sciatic notch	1	2	3	4 (5)
	a. angle L 65° R 60°				
*21.	pubic angle	1	2	3	(4) 5
23.	auricular surface	1	2	3	(4) 5
~~26.~~	sacrum	1	2	3	4 5
27.	superior inlet	1	2	3	(4) 5

Total Sex Score ÷ number of indicators = ≈ 4.5

108 ÷ 24

Summary Sex Male

Comments: This individual gives every indication of being male. The cranium is large, robust with a large supra orbital ridge and mastoid The occipital has a rugged appearance. The innominates show male traits as well: narrow sciatic notch, absence of a preauricular sulcus, large acetabulum, a high vertical ilium and a V shaped subpubic angle. In general The whole skeleton is robust.

MC Neel

BURIAL # NYABG Burr. 101 Cat. 843

AGE ASSESSMENT: mature adult, early-to-mid 30's

SEX ASSESSMENT: male

CONDITION OF PRESERVATION: excellent preservation minimal fragmentation Stage 0

BONES AND DENTITION PRESENT: almost complete skeleton, cranium, and mandible

OBSERVATIONS AND COMMENTS: pronounced supraorbital and glabellar "feature"; bone density; very large size; narrow sciatic notch; no preauricular sulcus; large, blunt mastoids; slight supramastoid torus; dilated vertebral borders; occipital bun; very pronounced nuchal crest; alveolar prognathism; squared chin; everted gonial angles; slight nasal sill; large, robust hands & feet;

Long bone epiphyses are fused; medial clavicular epiphyses are almost completely closed (late 20's) Sacral sutures is fused;

Age Assessment: dental attrition is minimal
sternal end ossification — Phase 4 (26-32 yrs.) [Dejean et al. 1980]
auricular surfaces — 4th decade (30-40 yrs.) [Lovejoy et al. 1985]
pubic symphysis — 4th-5th yrs. [Gilbert & Mckern 1973]
35-38 yrs. [Suchey-Brooks 1986]
sutural closure — 28-35 (appx. Trotter et al. 1952) accessory frontal suture

PATHOLOGIES AND ANOMALIES: vessel markings etched into ectocranial surfaces of frontal, along temples (bilateral); bilateral parietal foramina; bilateral supraorbital notch and foramen; "notched" squamous portion of the pronounced mastoid accessory foramen; mastoid; high arched occipital condyles; occipital condyles have T-shaped, almost bipartite appearance; section of maxillary sinuses not separate in; of medial orbital plates; slight inflammatory area along nasal sill; possible inflammatory area between supraorbital and zygomatic bone; pronounced - buccal caries activity and abscessing of posterior teeth (maxillary & mandibular); periodontal disease; X-shaped fronto-parieto-sphenoid & temporal sutures; coronal, sagittal and lambdoid sutures partially & partially fused ectocranially; sphenoid-temporo-parietal sutures are fused; marginal (slight) lipping of acetabula; iliac pillar on both innominates; marginal lipping of articular facets of hips; sternal end ossification of ribs; slight marginal lipping of sternal cavities; osteochondritic cysts in center of sternal cavities (more noticeable on right side and raised area in the center); bilateral AC arthritis; inflammation of rotator cuff area (bilateral); subchondral bone defects of medial ends of clavicles; articular facets on lateral ends of clavicles; enthesopathy of brachialis & pronounced development of supinator ridges attachments on ulnae; some slight marginal lipping of distal radii articular surfaces and osteochondritic cysts (grooves) in both of surfaces; bipartite sternum (2nd piece is extremely broad); cortical defects of sterno-clavicular ligaments; extremely robust lumbar vertebrae with small Schmorl's nodes on centers of superior & inferior surfaces of each centrum; Schmorl's nodes on centers of C6, C7, T1, T2, cervical vertebrae show pronounced ruggosity & eccentration of attachments; slight-to-moderate osteophytic lipping of lower thoracic vertebral articular facets; fusion of sternal end ribs of radii; pronounced Schmorl's nodes on inferior T7 and superior T8; pronounced pectoralis major attachments on anterior humeri;

PERSONAL NOTES FORM (M.C. HILL)[1] 10/4/94 MCH

BURIAL # NYABG, Bur. 101 Cat. 843

~~MEASUREMENTS~~: Pathology (continued)

master) interglia notch on patellae (bilateral); slight-to-moderate sclerotic linear periosteal striations along entire length of diaphysis and epiphysis of femora (more noticeable on distal metaphyses); lateral torsion of proximal right femur; a/p bowing of proximal femora; Poirier's facet (?) on posterior aspect of prox. right tibia; macroporotic resorptive pitting of distal femoral metaphyses; cortical erosion of anterior aspect of prox. femoral necks; cortical expansion of fibulae — becomes more pronounced going from prox. to distal diaphyses and esp. distal metaphyses; slight-to-moderate sclerotic periosteal striations along entire metaphyseal/diaphysis of fibulae; sclerotic linear periosteal along entire metaphyseal/diaphysis length of both tibiae; a/p bowing and anterior cortical expansion of tibiae (saber shin); platycnemia; slight abrasion and microporosity of all articular surfaces of the leg: femora, tibiae, patellae; pronounced extreme cystic/blastic erosion & inflammation of both feet — esp. in tarsals and metatarsals; numerous osteochondritic cysts in hands and feet; several sesamoid bones in feet; elevation on posterior aspect of lateral epicondyle of the right femur

cervical erosion

⇒ Addendum: healed (bifurcated) fracture of spinous process of T12 on left side of mid-line (non-union fracture that splits the spinous process in two). An identical fracture is seen on T12 (a woman).

NOTES:

RADIOGRAPH? : PHOTO? : Yes, see photo logue

PERSONAL NOTES FORM (M.C. HILL)2

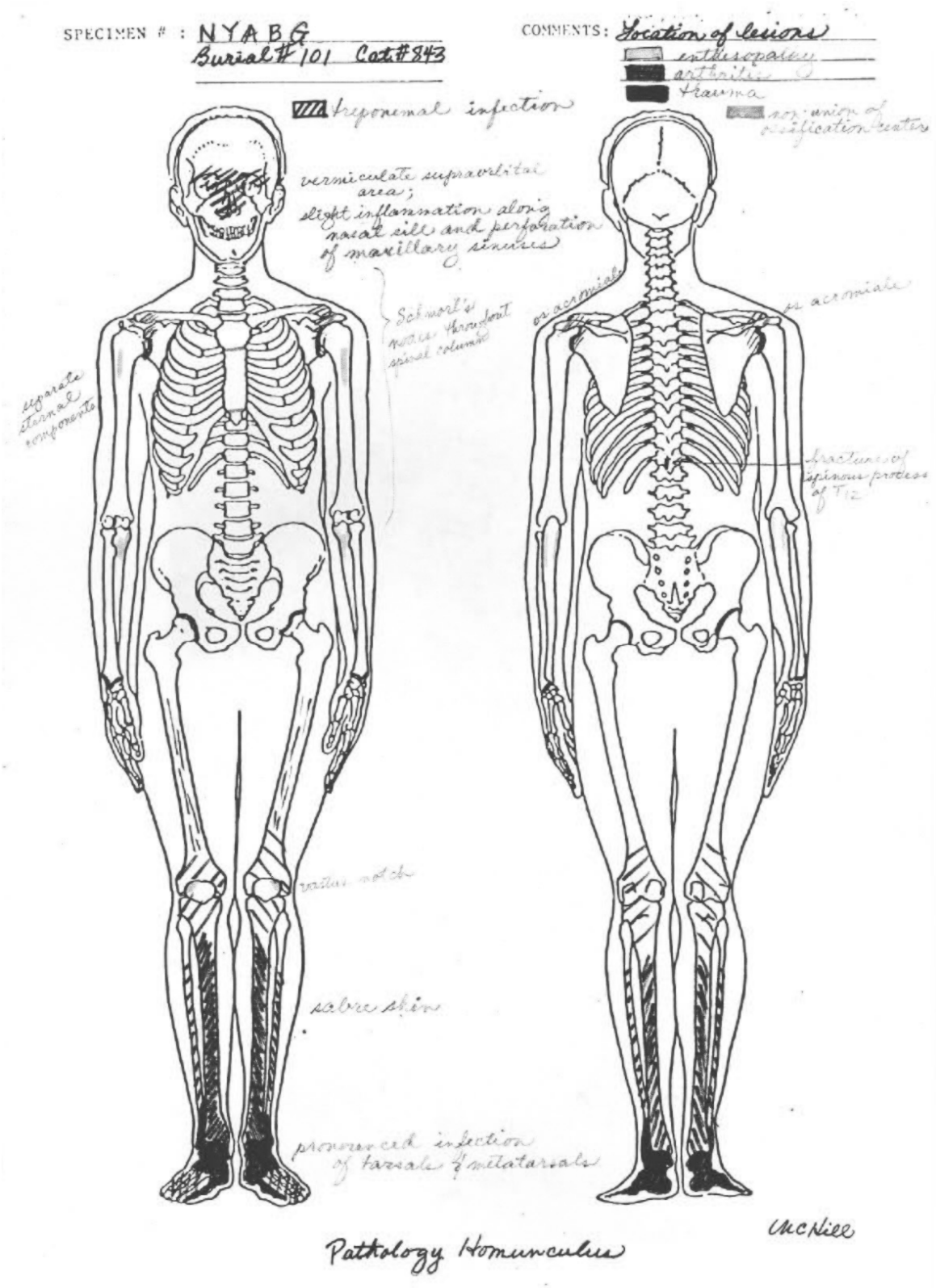
SPECIMEN # : NYABG
Burial #101 Cat #843
COMMENTS: location of lesions
enthesopathy
arthritis
trauma
non-union of ossification centers
treponemal infection
vermiculate supraorbital area; slight inflammation along nasal sills and perforation of maxillary sinuses
Schmorl's nodes throughout spinal column
os acromiale
os acromiale
separate sternal components
fractures of spinous process of T12
saber shin
pronounced infection of tarsals & metatarsals
Pathology Homunculus

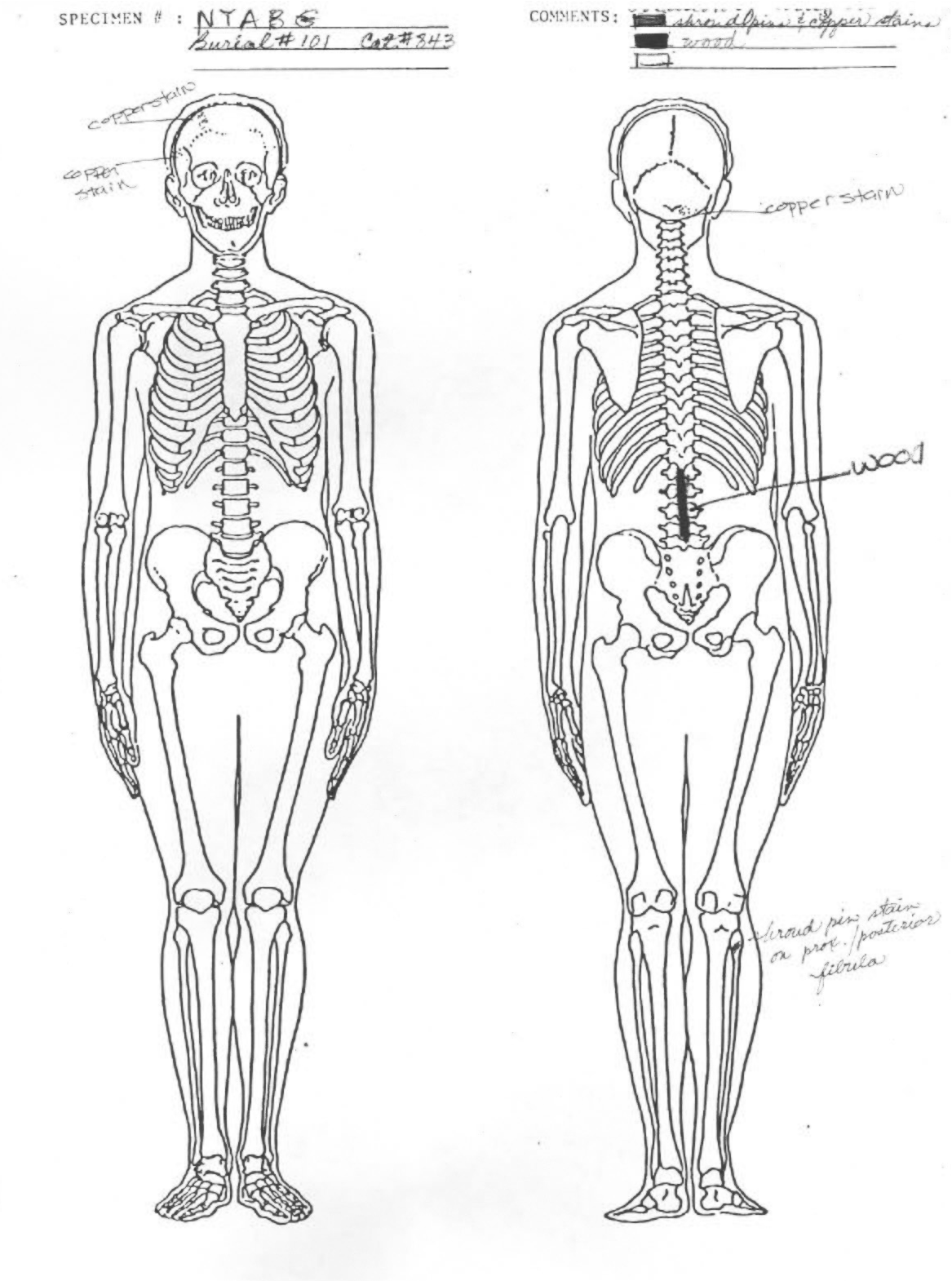
SPECIMEN # : NTABG
Burial #101 Cat #843
COMMENTS: shroud pins & copper stains
wood
copper stain
copper stain
copper stain
wood
shroud pin stain on prox. posterior fibula

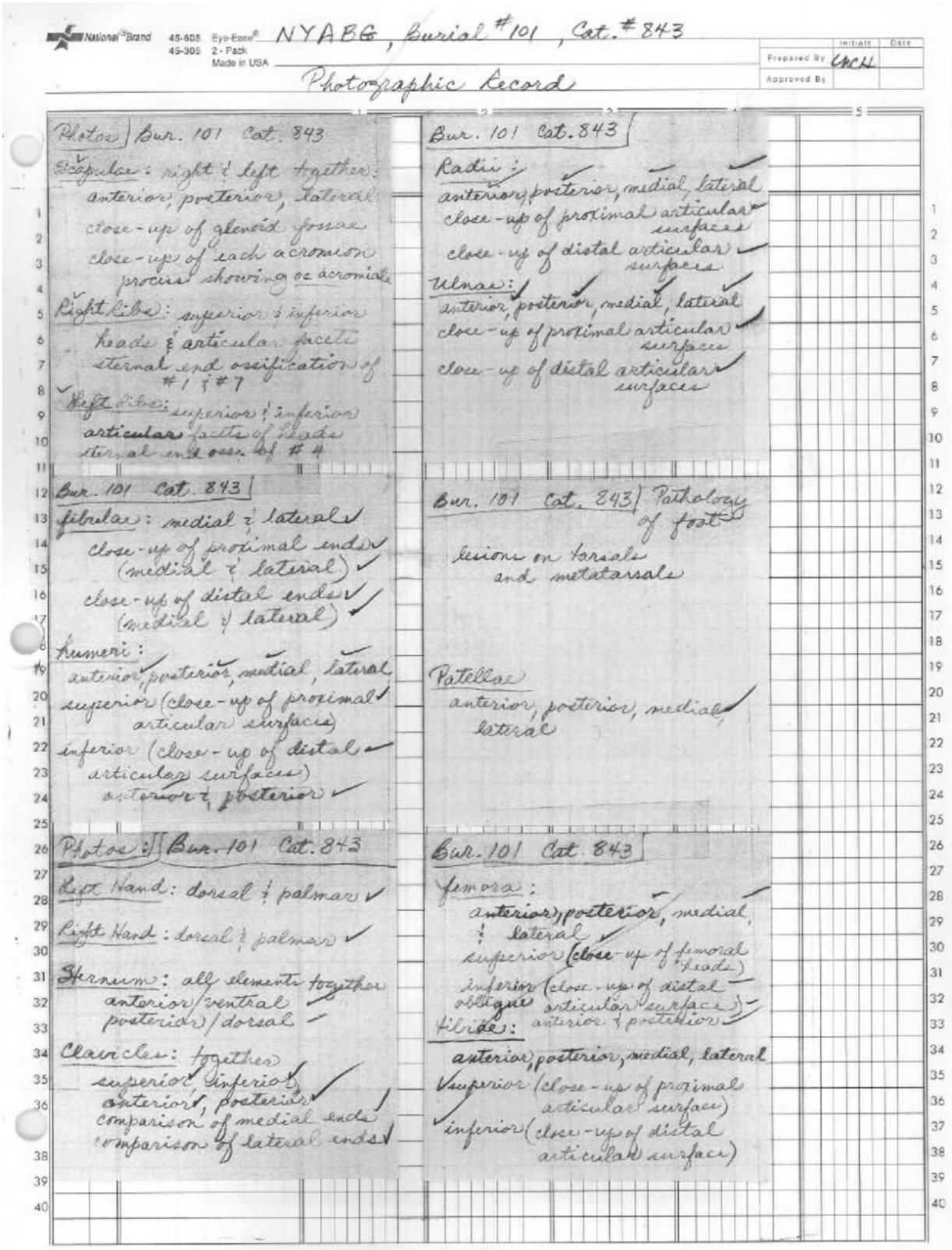

National Brand 45-605 45-305 Eye-Ease® 2-Pack Made in USA

NYABG, Burial #101, Cat. #843

Photographic Record

	Initials	Date
Prepared By	LACH	
Approved By		

Photos | Bur. 101 Cat. 843
Scapulae: right & left together:
anterior, posterior, lateral
close-up of glenoid fossae
close-up of each acromion process showing oc acromiale
Right Tibia: superior & inferior
heads & articular facets
sternal end ossification of #1 & #7
Left tibia: superior & inferior
articular facets of heads
sternal end ossif. of # 4

Bur. 101 Cat. 843
Radii:
anterior, posterior, medial, lateral
close-up of proximal articular surfaces
close-up of distal articular surfaces
Ulnae:
anterior, posterior, medial, lateral
close-up of proximal articular surfaces
close-up of distal articular surfaces

Bur. 101 Cat. 843
fibulae: medial & lateral
close-up of proximal ends (medial & lateral)
close-up of distal ends (medial & lateral)
humeri:
anterior, posterior, medial, lateral
superior (close-up of proximal articular surfaces)
inferior (close-up of distal articular surfaces)
anterior & posterior

Bur. 101 Cat. 843 Pathology of foot
lesions on tarsals and metatarsals

Patellae
anterior, posterior, medial, lateral

Photos II Bur. 101 Cat. 843
Left Hand: dorsal & palmar
Right Hand: dorsal & palmar
Sternum: all elements together
anterior/ventral
posterior/dorsal
Clavicles: together
superior, inferior,
anterior, posterior
comparison of medial ends
comparison of lateral ends

Bur. 101 Cat. 843
femora:
anterior, posterior, medial & lateral
superior (close-up of femoral heads)
inferior (close-up of distal articular surfaces)
obliques
fibulae: anterior & posterior
anterior, posterior, medial, lateral
superior (close-up of proximal articular surfaces)
inferior (close-up of distal articular surfaces)

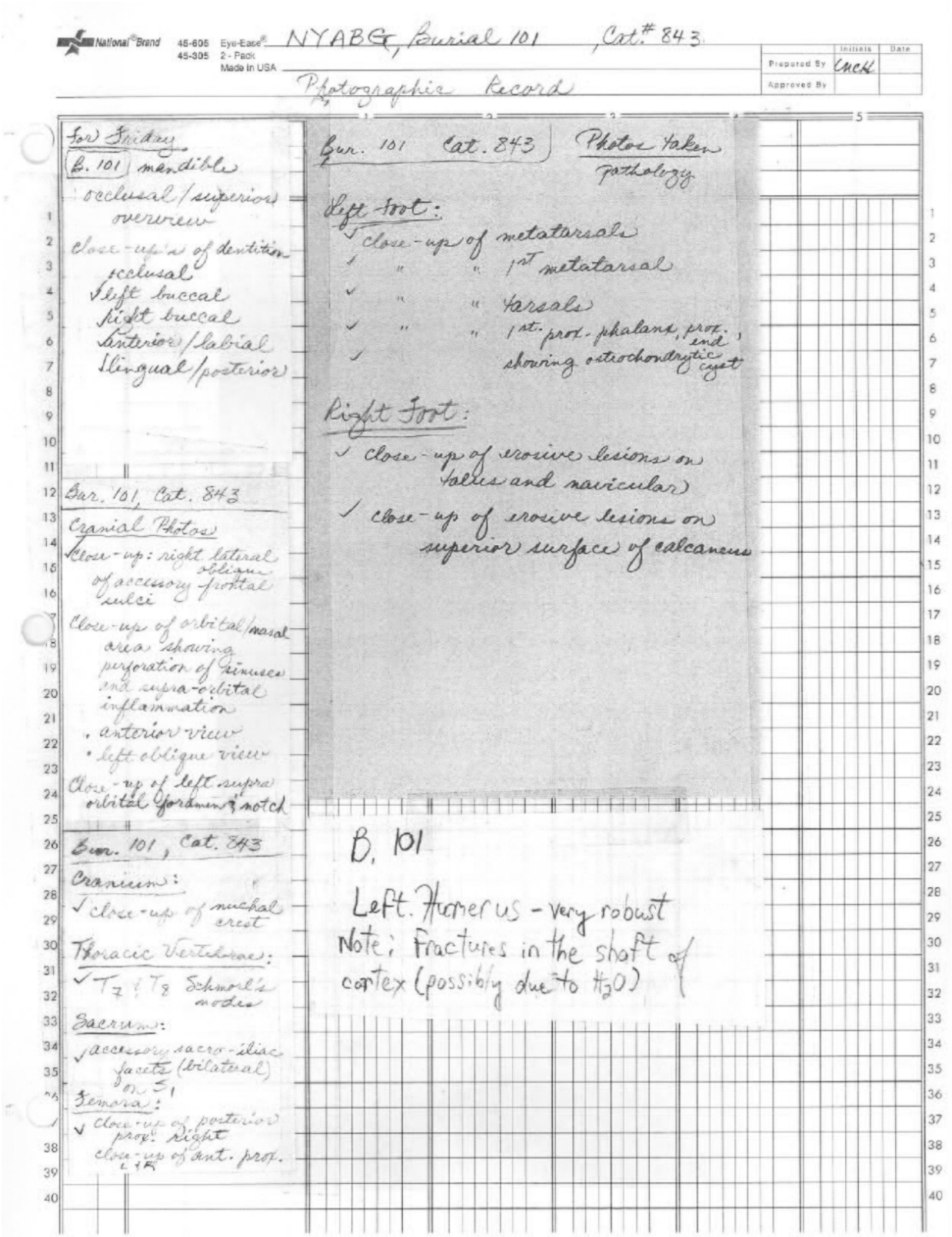
National Brand 45-605 Eye-Ease 45-305 2 - Pack Made in USA
NYABG, Burial 101, Cat.# 843
Photographic Record
Initials Date
Prepared By CMCH
Approved By
for Friday
B. 101 mandible
occlusal / superior overview
Close-up's of dentition
occlusal
left buccal
right buccal
anterior / labial
lingual / posterior
Bur. 101 Cat. 843
Cranial Photos
Close-up: right lateral oblique of accessory frontal sulci
Close-up of orbital / nasal area showing perforation of sinuses and supra-orbital inflammation
anterior view
left oblique view
Close-up of left supra orbital foramen & notch
Bur. 101, Cat. 843
Cranium:
close-up of nuchal crest
Thoracic Vertebrae:
T7 & T8 Schmorl's nodes
Sacrum:
accessory sacro-iliac facets (bilateral) on S1
Femora:
close-up of posterior prox. right
close-up of ant. prox. L & R
Bur. 101 Cat. 843 Photos taken Pathology
Left foot:
close-ups of metatarsals
" " 1st metatarsal
" " tarsals
" " 1st prox. phalanx, prox. end showing osteochondritic cyst
Right Foot:
close-up of erosive lesions on talus and navicular
close-up of erosive lesions on superior surface of calcaneus
B. 101
Left Humerus - very robust
Note; Fractures in the shaft of cortex (possibly due to H2O)

NEW YORK AFRICAN BURIAL GROUND PROJECT PHOTOGRAPHIC RECORD

BURIAL# 10 CATALOG# 843

BEGINNING DATE ___/___/___ ENDING DATE ___/___/___ P95/08/2 P96/264/2 P-96-266/2

STANDARD PHOTOGRAPHIC ASSESSMENTS

SKELETAL ELEMENTS	VIEW/SURFACES/INDICATOR(S) ✓ = PHOTOGRAPHED	
POSTCRANIAL ELEMENTS:		
femora	anterior, posterior, medial, lateral	✓
	proximal close-up's: anterior, medial, posterior distal close-up's: anterior, posterior, distal/oblique	✓ ✓
tibiae	anterior, posterior, medial, lateral	✓
	close-up of prox. articular surfaces close-up of dist. articular surfaces	✓ ✓
fibulae	medial; lateral	✓
	close-up of prox. articular surfaces close-up of dist. articular surfaces	✓ ✓
Humeri	anterior, posterior, medial, lateral	✓
	prox. close-up's: anterior, medial, posterior dist. close-up's: anterior, posterior, dist./oblique	✓ ✓
Radii	anterior; posterior; medial; lateral	✓
	close-up of distal articular surface and prox. art. surface	✓
Ulnae	anterior; posterior; medial; lateral	✓
	close-up of proximal half: anterior;medial;lateral close-up of distal articular surface	✓ ✓
Patellae	anterior; posterior (medial & lateral, if pathological)	✓
Clavicles	superior; inferior, ant, post. close-up of medial articular surface	✓ ✓
	close-up of medial inferior surface close-up of lateral inferior surface	✓ ✓

NEW YORK AFRICAN BURIAL GROUND PROJECT PHOTOGRAPHIC RECORD

P-96-264/2, P96 265/2

IAL# 101 CATALOG#

P-94/87, 88

BEGINNING DATE ___/___/___ ENDING DATE ___/___/___

P-94/91-95

NDARD PHOTOGRAPHIC ASSESSMENTS

SKELETAL ELEMENTS	VIEW/SURFACES/INDICATOR(S) ✓ = PHOTOGRAPHED	
Scapulae	anterior; posterior, lat. close-up of glenoid cavities, closeup of a animale	✓ ✓
Innominates	anterior; posterior close-up of iliac crests	✓ ✓ L R ✓ ✓
	close-up of auricular platform surfaces close-up of acetabula	✓ ✓ P-94-93 ✓ ✓
	close-up of pubic symphyses	✓ ✓
Hands	dorsal; volar (palmar)	✓ ✓
Feet	dorsal; volar (plantar)	✓ P-94-92
Tali & Calcanei	close-up of articular surfaces	✓
Sternum	ventral (anterior); dorsal (posterior)	✓
Ribs	Left: superior; inferior Right: superior; inferior	✓ ✓
Cervical Vertebrae	In Line: superior; inferior Stacked Together: anterior;posterior; L. lateral;R. lateral	✓ ✓
Thoracic Vertebrae	In Line: superior; inferior Stacked Together: anterior;posterior;L. lateral; R. lateral	✓ ✓
Lumbar Vertebrae	In Line: superior; inferior Stacked Together: anterior;posterior;L. lateral; R. lateral	✓ ✓
Sacrum	anterior; ~~posterior;~~ left lateral and right lateral (together) ~~close up of auricular platform~~	✓
~~Coccyx~~	~~general inventory: anterior~~	
~~Cervical~~	~~general inventory: anterior~~	

NEW YORK AFRICAN BURIAL GROUND PROJECT PHOTOGRAPHIC RECORD

BURIAL# [101] CATALOG# [ ] p94-101, 102 p94/83, 4

BEGINNING DATE ___/___/___ ENDING DATE ___/___/___

STANDARD PHOTOGRAPHIC ASSESSMENTS

SKELETAL ELEMENTS	VIEW/SURFACES/INDICATOR(S) ✓ = PHOTOGRAPHED	
Cranium w/ mandible	In Frankfurt Plane: anterior; L. lateral; R. lateral	✓
	superior; inferior; posterior; ~~endocranial view~~	✓
Maxillae	left lateral; anterior; right lateral; occlusal	✓
Mandible	left lateral; anterior; right lateral; occlusal	✓
Dental Close-Up's	maxillae and mandible in occlusion: left lateral; anterior; right lateral	✓

NEW YORK AFRICAN BURIAL GROUND PROJECT PHOTOGRAPHIC RECORD

P-96-114

BURIAL# 101 CATALOG# 843

BEGINNING DATE 5/10/96 ENDING DATE 5/10/96

SKELETAL ELEMENTS	VIEW/SURFACES/INDICATOR(S) ✓ = PHOTOGRAPHED	
Maxillary + Mandibular Dentition	Anterior, R. Lateral, L. Lateral, occlusal - general inventory Max Mand	KMH KMH
Maxillary Dentition	Close-up - Anterior R. Lateral L. Lateral Occlusal All-Teeth - Pathologies	KMH
Mandibular Dentition	Close-up - Anterior, R. Lateral, L. Lateral, occlusal All teeth - Pathologies	KMH
Central Max Incisors LI' RI'	Close-up - Anterior, Occlusal -> Enam. Hypocalcification Enam. Hypopl. Pitting, Chipping	KMH
L PM_2	Close-up Occlusal - three lingual cusps	KMH

NYABG Burial 101
Cat.# 843
Histology Sample

New York African Burial Ground Project
Howard University
Skeletal Sampling Document

Identification: Burial # 101 C# 843 Element Rib Sample d midshaft

Quality: Preservation status (d) excellent Soil type clay (?)

Demography: Sex male Age early to mid 30's

Comments: _____

Date sampled: 8/8/95

Destination: Univ of Oklahoma

Initials: Measurement _____ Radiography _____ Sectioning _____

New York African Burial Ground Project
Howard University
Skeletal Sampling Document

Identification: Burial # 101 CAT # 843 Element L, R 1b Sample mid-shaft

Quality: Preservation status Stage 0 (good) Soil type Clay (?)

Demography: Sex MALE Age MATURE ADULT (early-mid 30s)

Femur measurements: Maximum length — Bicondylar length —

Comments: _____

Date sampled: 8 / 10 / 95

Destination: Univ. of Oklahoma

Purpose: _____

Initials: Measurement — Radiography — Sectioning KMH

Appendix C

PRESERVATION STATUS CODES FOR NEW YORK AFRICAN BURIAL GROUND

APPENDIX C

PRESERVATION CODES

S. S. Mahoney and C. Null

In order to get an idea for overall preservation of each entire skeleton, the Inventory database was modified to create a preservation database.

The Inventory database provides a completeness assessment for each element, or portion of the element, of the individual's skeleton. The completeness is based primarily on the "Chicago Standards" guidelines:

1 = >75% present
2 = 25% to 75% present
3 = <25% present
8 = Partially observable (25% to 75%)
9 = Complete but unobservable
Blank = missing element

These values in the Inventory database were recoded to create the following preservation value labels:

1 = good
2 = fair
3 = poor
4 = missing

In order to modify the inventory database to make it useful as a preservation database in SPSS, the completeness value had to be modified to a preservation value. Codes 1, 2, and 3 did not change. Code 8 (partially observable) was recoded to 2 (fair condition), Code 9 (complete but unobservable) was recoded to 3 (poor condition), and blank entries were modified to Code 4 (Missing)

The preservation database was split into two databases: one for cranial preservation and another one for post-cranial preservation. Each database had a new variable attached for the mean of all the preservation codes for every bone in that section. The mean formula calculated the average of all the element codes for each burial, resulting in one number. The cranial and post-cranial preservation means were then placed together for comparative purposes (see the attached table).

There are two issues that must be taken into consideration with this database.

Some individuals (e.g. Burial 101), had consistent preservation throughout the skeleton, and the final preservation code should be a very good representation of overall condition. Other burials, however, had been modified by nineteenth- and twentieth-century ditches, subsequent burials, plumbing, and other trenching which cut burials in half or removed a good portion of the remains. These individuals (e.g., Burial Nos. 428, 120, or 200) might have good preservation in the upper torso (1 to 2) but the missing remains from the lower half of the body would place the final preservation mean closer to 4 (missing).

The final mean for the post cranial preservation codes will tend to be weighted heavily toward the long bones. The clavicles each have one preservation code linked to them. The long bones, however, were assessed for the proximal and distal ephiphyses as well as the proximal, medial and distal third of the diaphysis. This results in five preservation codes for each long bone versus one preservation code for another element (i.e., the clavicle), resulting in a mean that is more indicative of long-bone preservation. For the cranial elements, the ear bones (malleus, incus, and stapes), which are rarely recovered, each have a code for both sides, resulting in a set of six missing codes for most of the cranial material.

Taking these qualifications into consideration, the preservation codes provide an efficient and useful method of assessing the condition of the remains.

Appendix C: Preservation Codes for NYABG Burials

Codes: 1.00–1.99 = Good 2.00–2.99 = Fair 3.00–3.99 = Poor 4 = Missing

Burial #	Crania	Post-Crania
1.0	2.62	2.79
2.0	3.00	4.00
3.0	2.89	3.99
4.0	2.89	4.00
4.1	2.62	4.00
5.0	3.70	4.00
6.0	1.97	1.26
7.0	1.92	1.96
8.0	4.00	4.00
9.0	2.19	2.23
10.0	1.95	2.37
11.0	2.73	2.52
12.0	1.73	1.59
13.0	4.00	4.00
14.0	2.38	3.53
15.0	4.00	3.84
16.0	3.08	3.09
17.0	2.73	3.38
18.0	2.78	3.43
19.0	4.00	4.00
20.0	4.00	3.20
21.0	4.00	4.00
22.0	2.70	2.49
23.0	2.27	2.49
24.0	3.54	3.45
25.0	2.57	1.84
26.0	3.81	3.87
27.0	3.43	3.96
28.0	3.68	3.98
29.0	4.00	3.66
30.0	2.38	3.54
31.0	2.81	3.26
32.0	2.57	1.70
33.0	3.97	3.93
34.0	4.00	4.00
35.0	2.30	2.40
36.0	4.00	3.72
37.0	2.14	1.16
38.0	2.95	3.82
39.0	2.19	2.57
40.0	2.38	1.70
41.0	4.00	3.89
42.0	3.65	2.88
43.0	3.22	3.85
44.0	4.00	4.00
45.0	3.41	3.19
46.0	3.89	3.53
47.0	2.70	3.06
48.0	4.00	4.00
49.0	2.05	2.66
50.0	4.00	4.00
51.0	2.35	1.29
52.0	4.00	4.00
53.0	3.84	3.40
54.0	4.00	3.55
55.0	2.76	2.10
56.0	1.70	1.54
57.0	4.00	4.00
58.0	2.32	2.12
59.0	3.70	3.77
60.0	3.65	3.88
63.0	2.46	1.63
64.0	3.73	3.79
65.0	3.92	4.00
66.0	4.00	4.00
67.0	4.00	1.68
68.0	2.68	2.89
69.0	4.00	2.95
70.0	4.00	2.68
71.0	2.59	1.19
72.0	2.84	3.49
73.0	2.41	3.07
75.0	3.92	3.99
76.0	2.11	2.27
77.0	3.95	4.00
78.0	2.65	3.94
79.0	3.86	4.00
80.0	4.00	4.00
81.0	4.00	3.44
82.0	2.27	3.63
83.0	3.97	4.00
84.0	3.03	3.57
85.0	3.97	4.00
86.0	2.19	2.19
87.0	3.65	4.00
88.0	4.00	3.94
89.0	1.76	1.99
90.0	2.19	2.49
91.0	2.30	2.45
93.0	4.00	4.00
94.0	3.95	3.88
95.0	2.27	2.14
96.0	2.51	3.00
97.0	2.51	2.84
98.0	3.89	3.97
99.0	3.84	3.91
100.0	4.00	4.00
101.0	1.84	1.23
102.0	4.00	4.00
103.0	4.00	3.01
104.0	3.41	2.35
105.0	3.81	2.81
105.1	3.95	3.89
106.0	3.54	3.47
107.0	2.19	1.48
108.0	3.11	3.02
109.0	3.97	4.00
110.0	3.95	4.00
111.0	3.89	3.93
112.0	3.92	3.97
113.0	3.97	3.98
114.0	3.05	2.46
115.0	2.46	2.77
116.0	3.16	2.39
117.0	3.86	3.80
118.0	4.00	4.00
119.0	2.81	3.15
120.0	2.57	3.70
121.0	3.41	3.97
122.0	2.19	1.19
123.0	3.84	4.00
124.0	3.70	4.00
125.0	4.00	3.74
126.0	3.30	3.48
127.0	3.95	4.00
128.0	3.84	3.94
130.0	3.11	3.13
131.0	4.00	4.00
132.0	3.70	2.67
133.0	3.41	3.08
134.0	2.68	2.34
135.0	2.32	1.33
136.0	4.00	4.00
137.0	3.89	3.34
138.0	2.46	1.42
142.0	2.30	3.44
143.0	2.73	3.52
144.0	4.00	3.82
146.0	3.59	3.43
147.0	2.54	2.30
148.0	3.11	3.66
149.0	3.95	3.90
150.0	2.51	2.37
151.0	2.62	2.03

Burial #	Crania	Post-Crania
152.0	4.00	4.00
153.0	2.92	3.73
154.0	2.00	1.65
155.0	4.00	3.63
156.0	4.00	3.49
157.0	4.00	3.90
158.0	2.35	1.26
159.0	2.78	3.20
160.0	3.08	4.00
162.0	3.84	3.41
163.0	4.00	3.65
164.0	3.76	3.12
165.0	3.35	2.87
166.0	3.68	3.50
167.0	2.51	3.85
168.0	4.00	3.42
169.0	3.54	3.85
170.0	4.00	3.84
171.0	2.43	1.55
172.0	3.78	2.67
173.0	3.81	3.90
174.0	2.41	2.35
175.0	2.70	2.43
176.0	2.86	2.09
177.0	2.92	3.48
178.0	4.00	3.74
179.0	2.03	1.39
180.0	2.35	2.07
181.0	4.00	2.50
182.0	3.68	3.94
183.0	3.54	4.00
184.0	4.00	3.38
185.0	1.95	2.49
186.0	2.92	3.21
187.0	2.78	1.63
188.0	4.00	3.80
189.0	4.00	3.93
190.0	2.97	3.35
191.0	2.70	2.38
192.0	2.86	3.34
193.0	2.81	2.83
194.0	3.43	2.90
195.0	2.86	1.29
196.0	2.49	2.38
197.0	2.35	1.85
198.0	4.00	4.00
199.1	2.62	2.53
199.2	4.00	3.91
200.0	2.05	3.25
201.0	3.78	4.00
202.0	2.89	3.49
203.0	3.81	3.80
204.0	4.00	3.85
205.0	2.57	1.18
207.0	2.43	3.07
208.0	4.00	3.80
209.0	2.84	2.30
210.0	2.16	1.16
211.0	4.00	4.00
212.0	3.95	3.56
213.0	3.00	2.83
214.0	2.30	2.23
215.0	3.97	3.77
216.0	3.11	3.63
217.0	4.00	2.79
218.0	4.00	4.00
219.0	3.78	3.37
220.0	4.00	4.00
221.0	2.05	2.65
222.0	4.00	3.18
223.0	2.41	1.26
224.0	3.19	3.91
225.0	3.32	2.13
226.0	3.95	4.00
227.0	3.70	3.77
228.0	4.00	3.55
229.0	2.62	3.43
230.0	2.24	2.12
233.0	4.00	4.00
234.0	3.95	4.00
235.0	2.24	1.76
236.0	3.16	3.88
237.0	4.00	3.91
238.0	2.27	1.80
239.0	3.00	3.73
240.0	4.00	3.99
241.0	2.62	1.57
242.0	1.65	1.40
243.0	2.00	1.27
244.0	3.54	2.51
245.0	3.38	3.64
247.0	2.54	3.18
248.0	4.00	3.73
249.0	4.00	4.00
250.0	3.84	3.95
251.0	3.08	3.50
252.0	2.97	2.48
253.0	2.65	2.55
254.0	3.05	3.82
255.0	4.00	4.00
256.0	2.41	2.34
257.0	2.92	1.66
258.0	4.00	4.00
259.0	3.05	2.26
260.0	3.95	3.93
262.0	2.05	1.52
264.0	4.00	3.99
265.0	3.95	4.00
266.0	2.76	1.98
267.0	3.43	3.59
268.0	3.89	3.70
269.0	3.32	3.94
270.0	2.76	3.01
271.0	2.43	2.70
272.0	4.00	4.00
273.0	4.00	3.98
274.0	2.84	3.93
275.0	4.00	3.92
276.0	2.76	1.59
277.0	4.00	3.93
278.0	2.49	1.37
279.0	4.00	3.52
280.0	4.00	3.82
281.0	2.95	3.93
282.0	1.81	2.79
283.0	3.76	3.98
284.0	2.30	2.82
285.0	2.27	1.68
286.0	3.00	2.60
287.0	4.00	2.87
288.0	4.00	3.96
289.0	2.86	3.42
290.0	3.00	3.46
291.0	3.95	4.00
292.0	4.00	3.99
293.0	4.00	3.84
294.0	3.78	4.00
295.0	3.46	3.80
297.0	4.00	3.27
298.0	3.73	4.00
299.0	2.22	1.84
300.0	3.89	4.00
301.0	4.00	3.93
302.0	4.00	3.71
303.0	3.97	4.00
304.0	3.81	4.00
305.0	2.57	3.26
306.0	1.97	2.40
307.0	3.81	3.88
308.0	3.78	3.95
309.0	4.00	3.05
310.0	2.27	2.01
311.0	3.81	3.90
312.0	3.16	3.37
313.0	2.70	1.94
314.0	2.46	2.79
315.0	2.43	2.08
316.0	2.62	1.82
317.0	4.00	3.87

Burial #	Crania	Post-Crania
318.0	4.00	3.98
319.0	4.00	3.77
320.0	3.92	4.00
321.0	3.19	3.93
322.0	4.00	3.55
323.0	2.08	1.54
324.0	3.14	2.09
325.0	2.68	2.24
326.0	2.38	1.33
327.0	2.38	2.36
328.0	1.81	1.94
329.0	2.35	2.14
329.1	4.00	3.80
330.0	3.00	4.00
331.0	3.27	4.00
332.0	2.65	3.02
333.0	2.78	1.91
334.0	4.00	4.00
335.0	2.57	1.37
336.0	3.97	4.00
337.0	2.51	1.46
338.0	2.43	3.16
339.0	4.00	4.00
340.0	2.65	3.05
341.0	2.38	2.66
342.0	2.16	1.27
343.0	2.03	1.74
344.0	2.49	3.91
345.0	2.84	3.96
346.0	3.16	3.23
347.0	3.95	4.00
348.0	3.27	3.77
349.0	4.00	3.95
350.0	3.84	3.79
351.0	2.51	2.41
352.0	3.35	3.27
353.0	2.27	2.15
354.0	1.86	1.80
355.0	4.00	4.00
356.0	3.76	3.73
357.0	2.89	3.03
358.0	4.00	3.91
360.0	4.00	4.00
361.0	2.16	3.21
362.0	2.86	3.98
363.0	2.43	2.00
364.0	3.78	3.13
365.0	4.00	3.57
366.0	2.70	2.06
367.0	3.89	4.00
368.0	2.38	1.67
369.0	1.86	1.24
370.0	3.95	3.98

Burial #	Crania	Post-Crania
371.0	2.35	3.05
372.0	3.89	4.00
373.0	2.24	3.48
374.0	3.30	3.70
375.0	2.95	2.99
376.0	2.30	2.16
377.0	2.81	3.52
379.0	2.05	1.32
380.0	1.97	1.86
382.0	3.54	3.72
383.0	1.59	1.59
384.0	1.70	3.46
385.0	1.95	1.43
386.0	2.78	3.59
387.0	2.27	2.76
388.0	2.57	3.18
389.0	2.65	3.13
390.0	4.00	3.81
391.0	3.03	2.26
391.1	4.00	3.80
392.0	2.97	1.98
393.0	2.68	3.40
394.0	4.00	3.75
395.0	2.54	2.41
396.0	3.46	1.66
397.0	2.78	2.30
398.0	3.73	3.94
399.0	3.03	3.12
400.0	2.84	2.91
401.0	4.00	4.00
402.0	4.00	4.00
403.0	2.05	4.00
404.0	3.95	3.85
405.0	2.76	3.07
406.0	2.76	2.66
407.0	4.00	4.00
408.0	4.00	3.87
409.0	4.00	4.00
410.0	4.00	3.43
412.0	3.65	4.00
413.0	2.84	2.52
414.0	2.84	2.46
415.0	3.19	3.04
416.0	4.00	3.60
417.0	3.89	3.78
418.0	2.84	2.32
419.0	2.19	1.66
420.0	3.81	3.15
420.1	4.00	3.98
420.2	4.00	3.80
423.0	4.00	4.00
424.0	4.00	4.00
426.0	4.00	4.00

Burial #	Crania	Post-Crania
427.0	2.97	2.20
428.0	2.41	3.08
429.0	4.00	4.00
430.0	4.00	4.00
431.0	4.00	3.95
432.0	4.00	4.00
433.0	4.00	4.00
434.0	4.00	4.00
435.0	4.00	4.00
436.0	4.00	4.00